



# Vets Cymru

# BSAVA

## ARRHYTHMIAS IN THE DOG

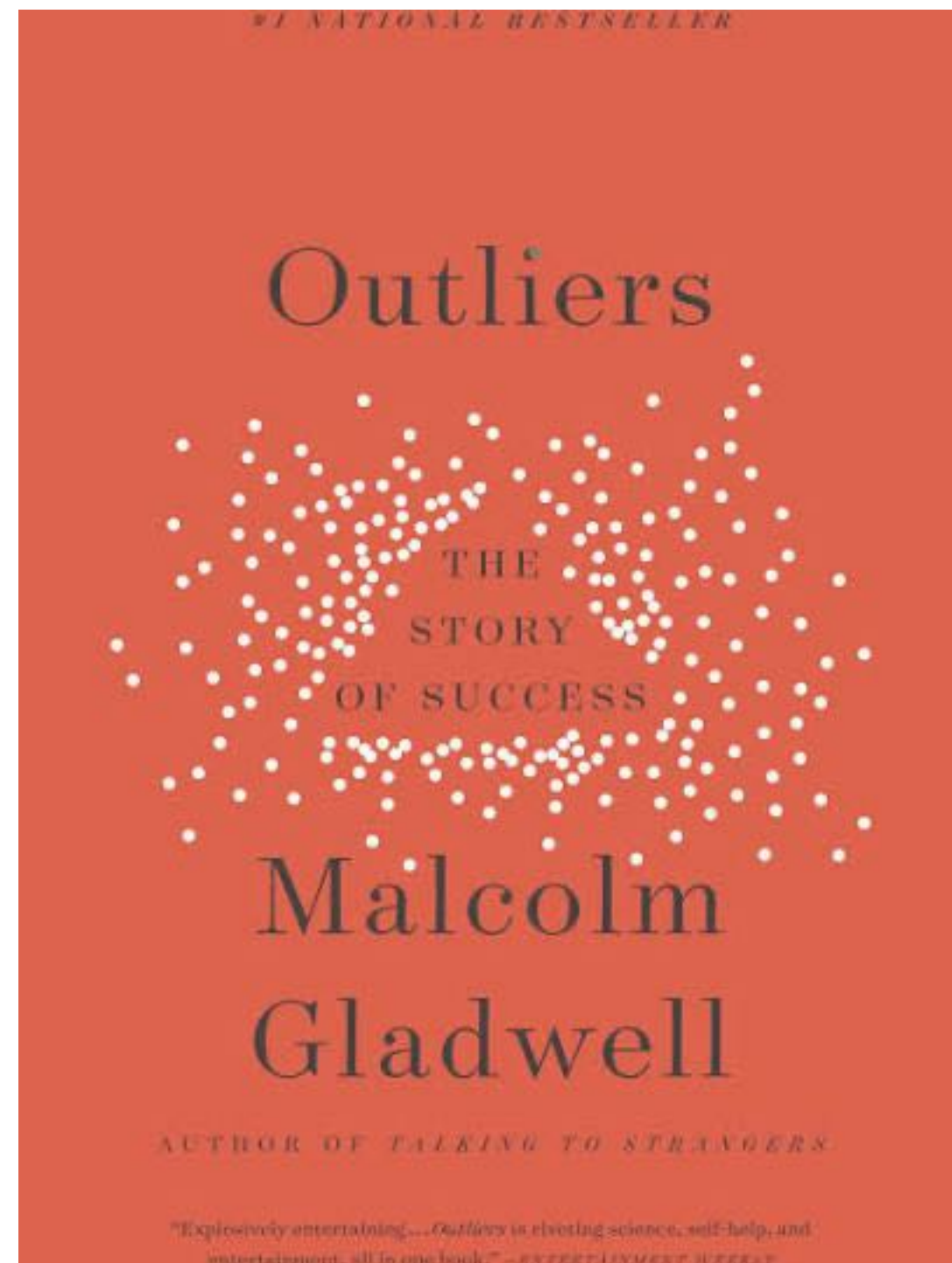
10,000 hours to become an expert, but only 20 hours to be proficient

**Dave Dickson**

**RCVS Recognised Specialist in Cardiology**

**HeartVets**





**IT TAKES 10,000 HOURS TO  
BECOME AN EXPERT IN  
SOMETHING**

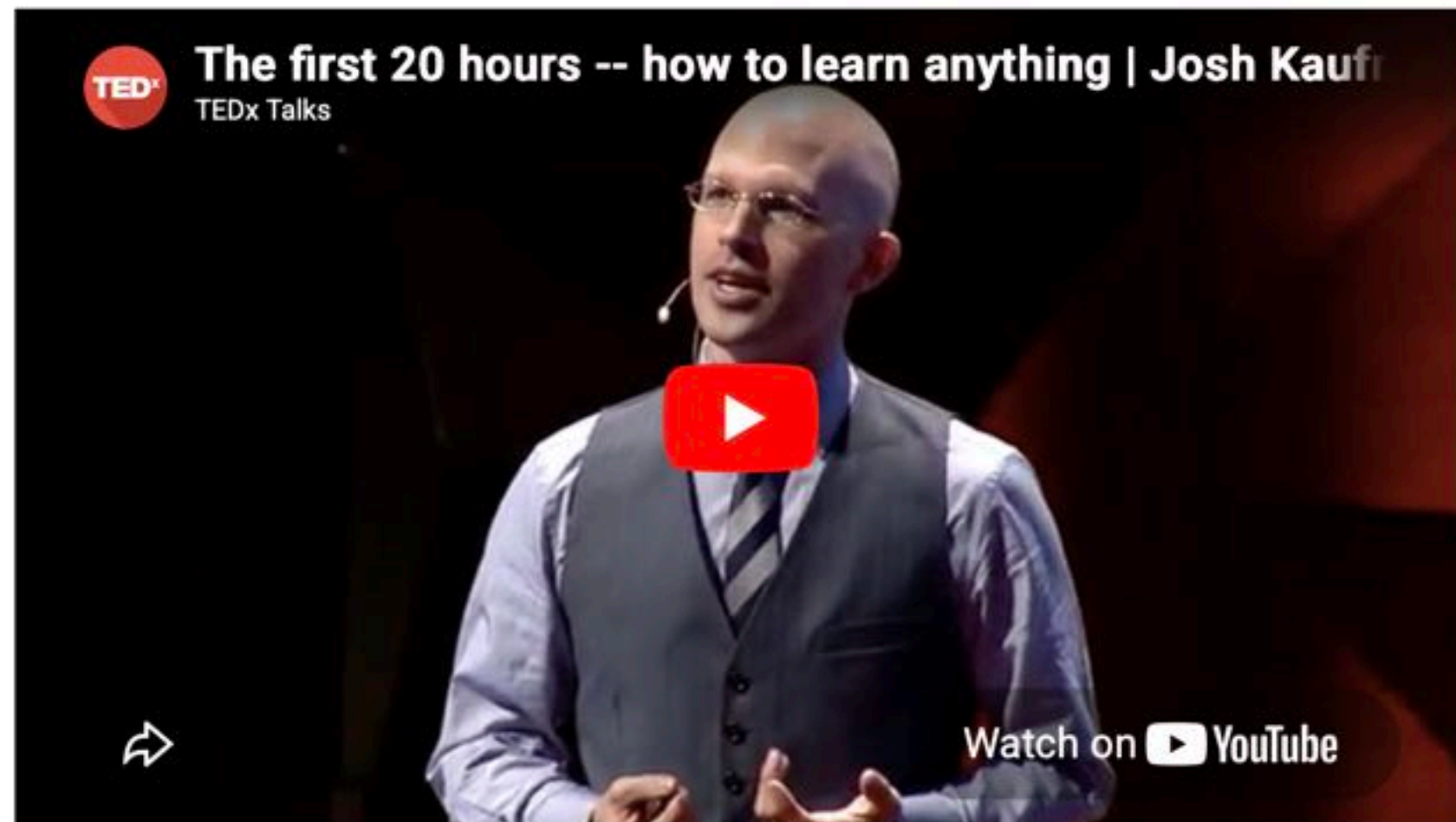



**IT TAKES 10,000 HOURS TO  
BECOME AN EXPERT IN  
SOMETHING**

**BUT YOU DON'T NEED TO BE AN EXPERT.**

# FORGET THE 10,000 HOURS THING



Josh Kaufman, TedX

## A LITTLE PRACTICE GOES A LONG WAY



# KEY POINTS

**EASY**

**HARDER**


**HARDEST**

**Know how to  
record an ECG**


**Know when to  
record an ECG**

**Be able to  
interpret ECGs  
properly**

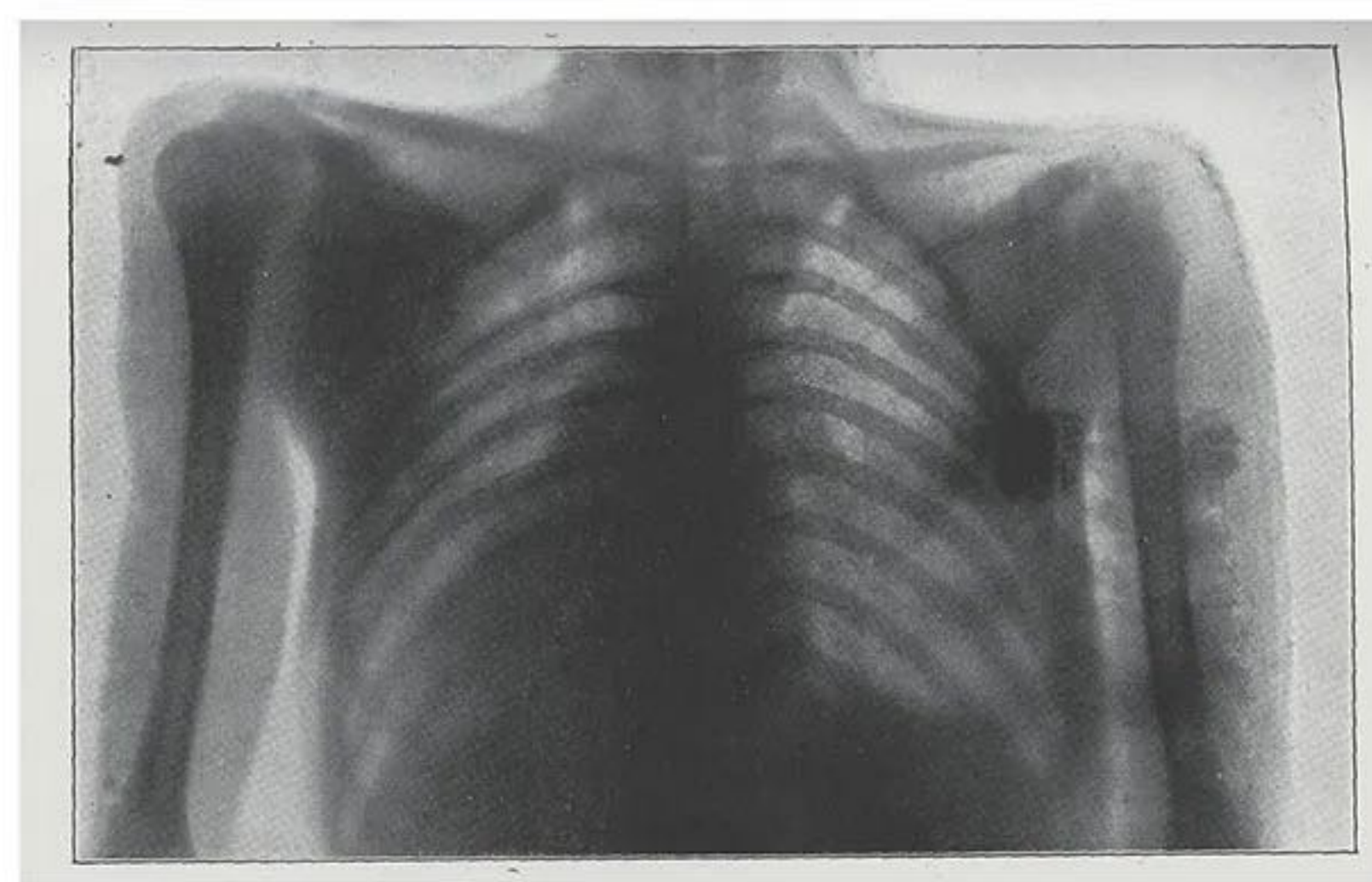
# WHY ARE ECGs SO HARD?



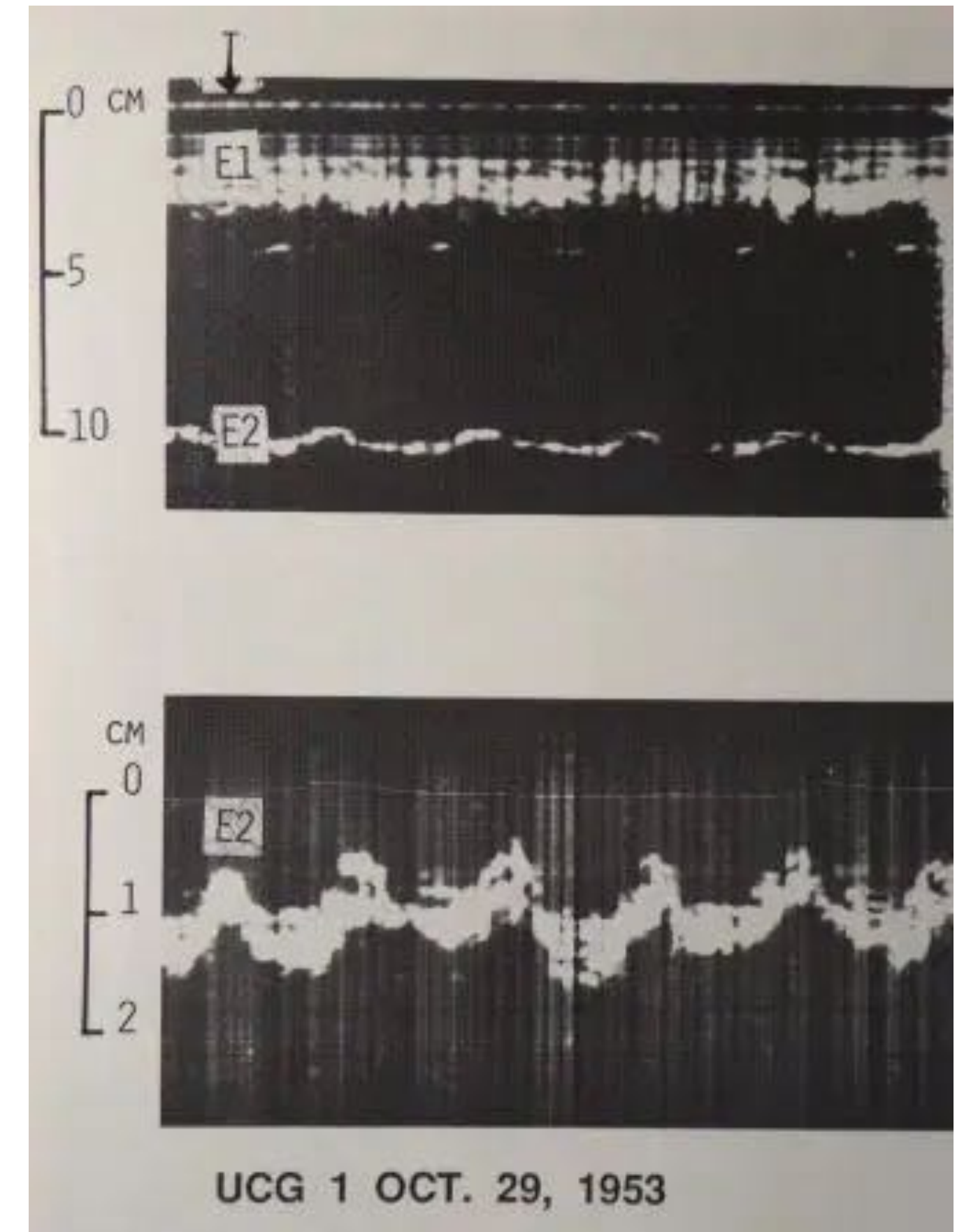
# THE EARLY DAYS



1887

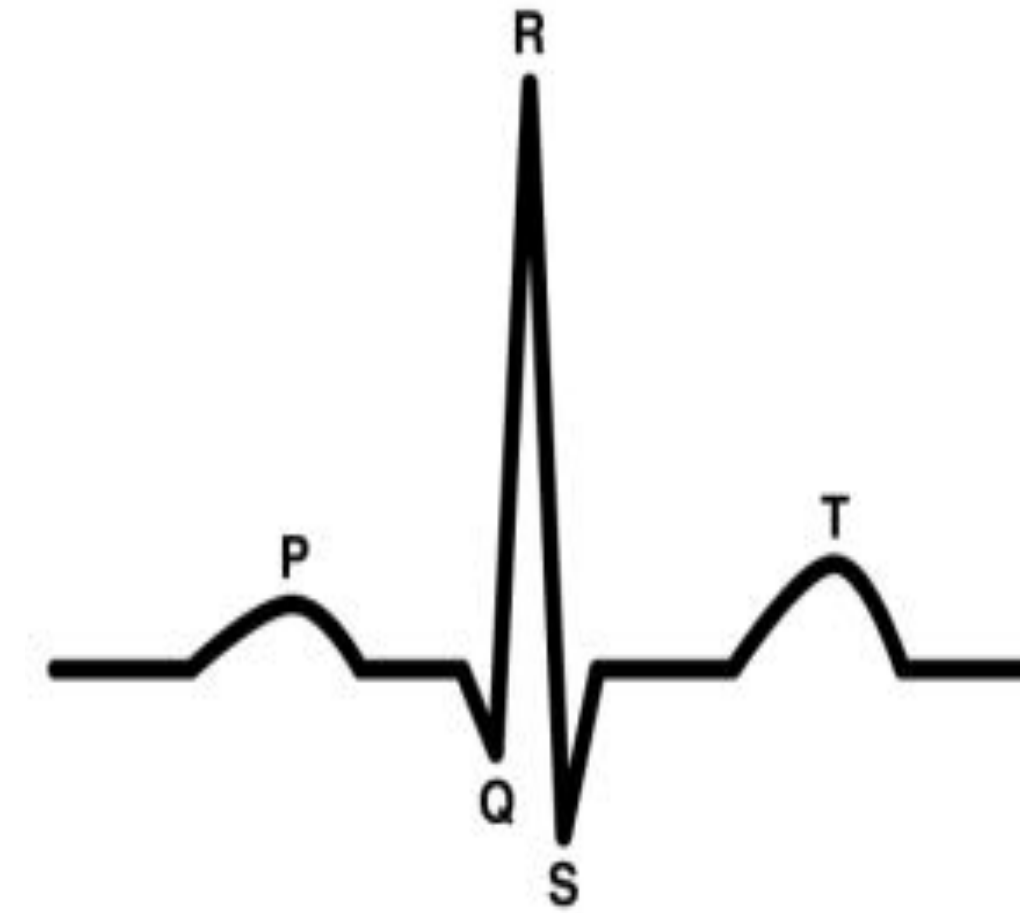
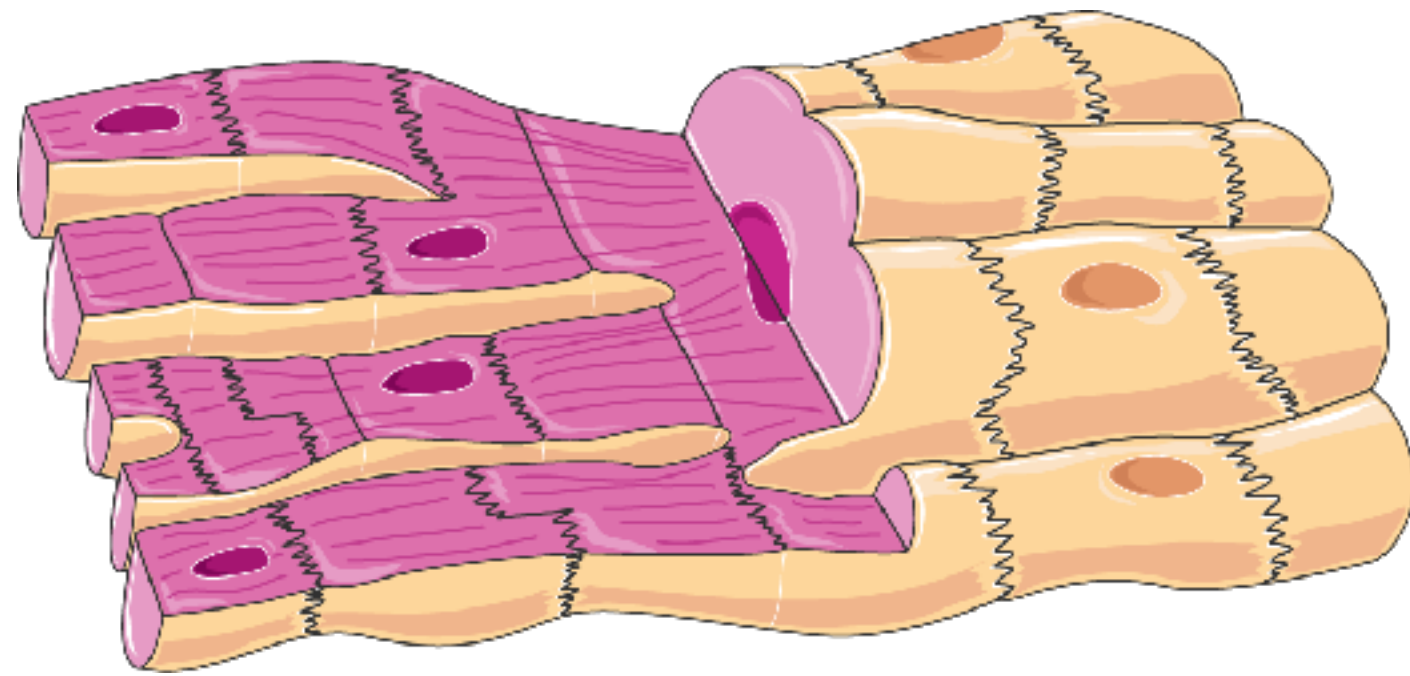


1896

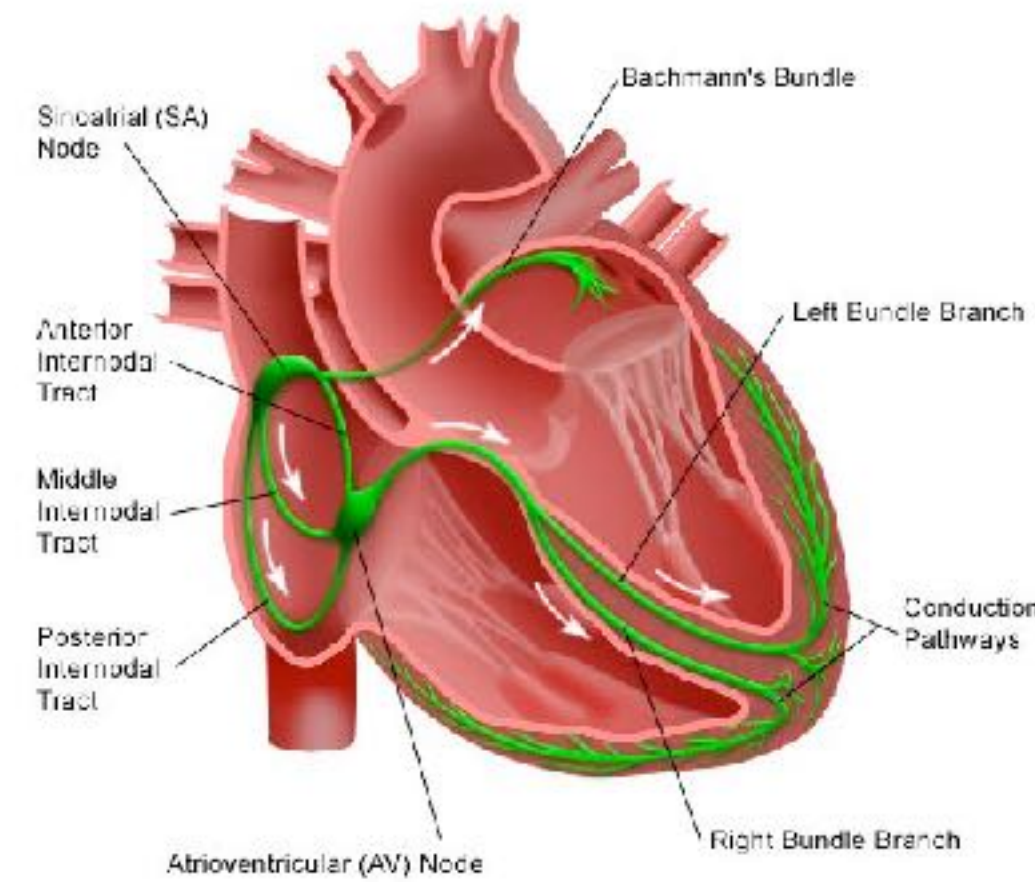


1953

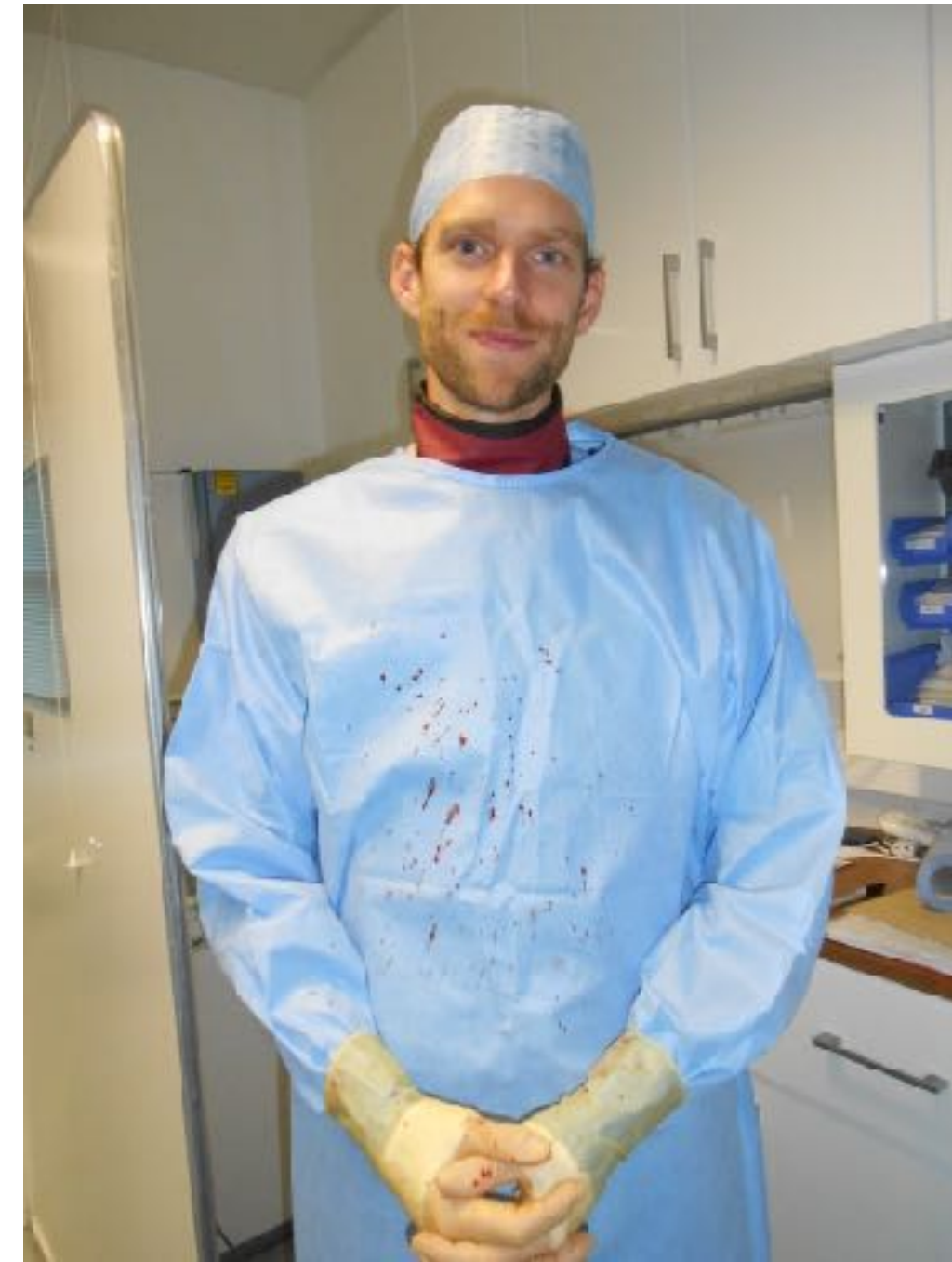# WHY ARE ECGs SO HARD?



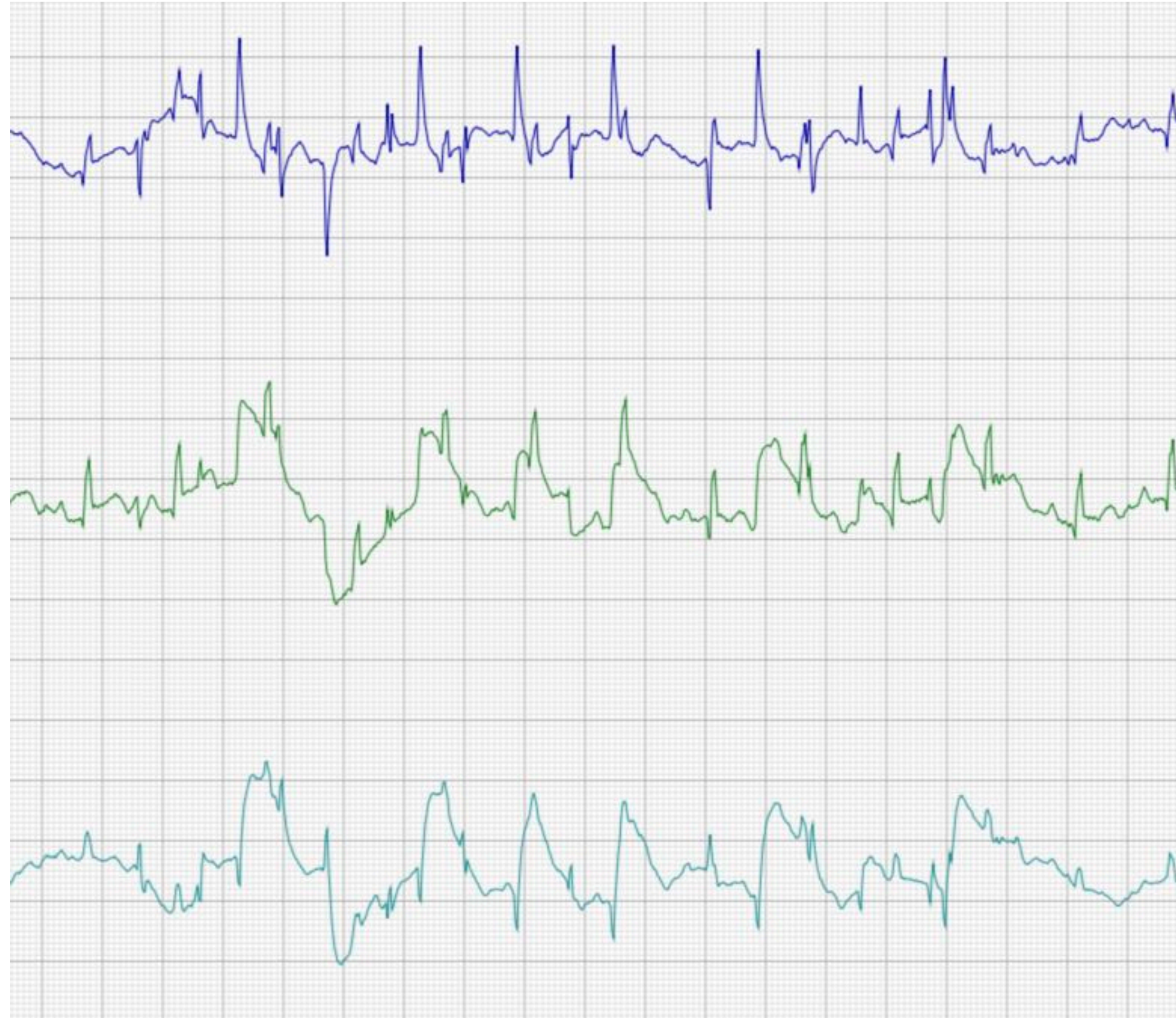
Electrical System of the Heart



# EVERYTHING YOU DON'T DO ALL THE TIME IS HARD



# WHY ARE ECGs SO HARD?



# SO LETS CHANGE THE PROBLEM

**Stop worrying about knowing how to interpret all ECGs**

Focus on three things to get better at:

**Know how to  
record an ECG**

**Know when to  
record an ECG**

**Follow a few  
key rules**

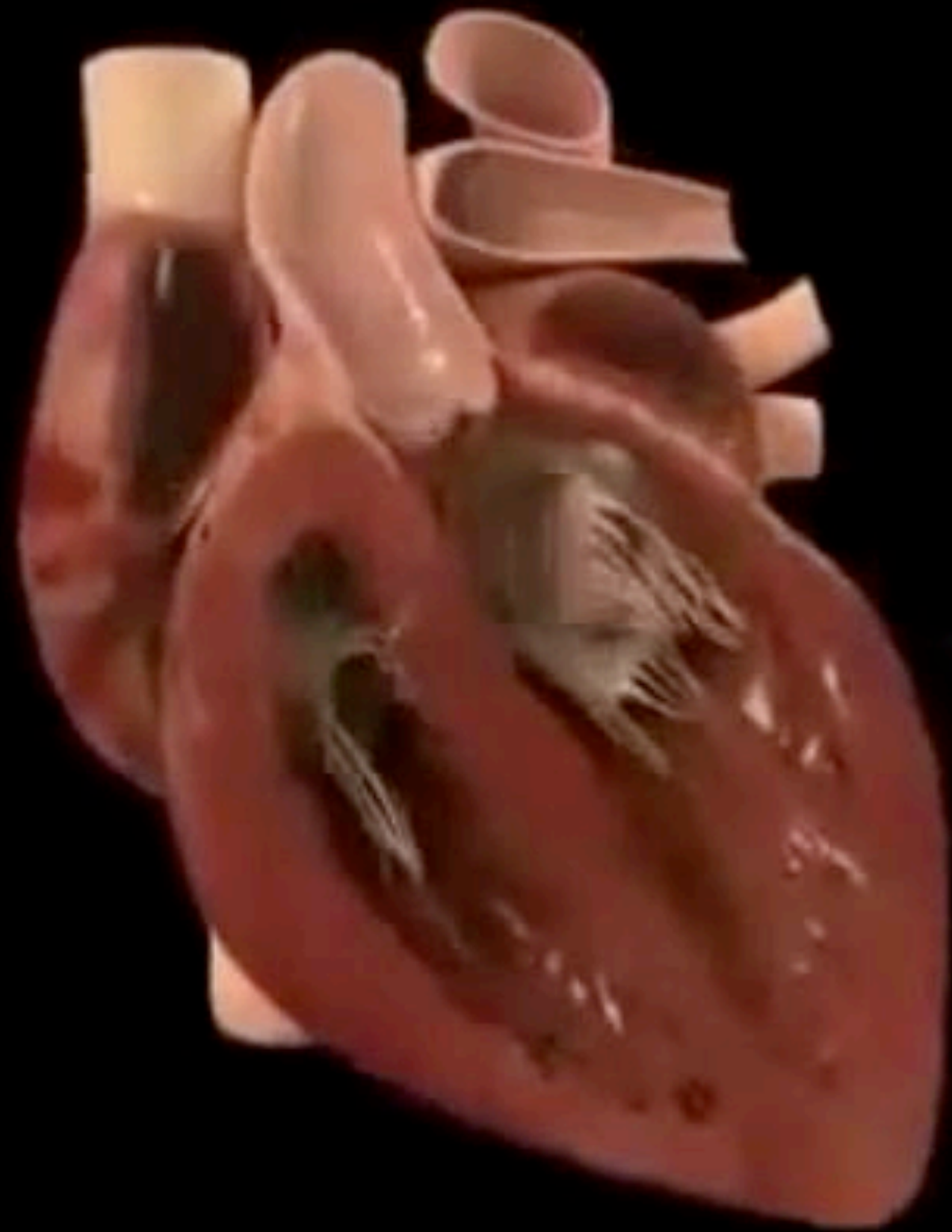
The rest you can ask for help on.




# WHAT IS AN ECG?

**WE NEED TO UNDERSTAND A BIT  
OF ANATOMY AND PHYSIOLOGY**


# Coordinated contraction



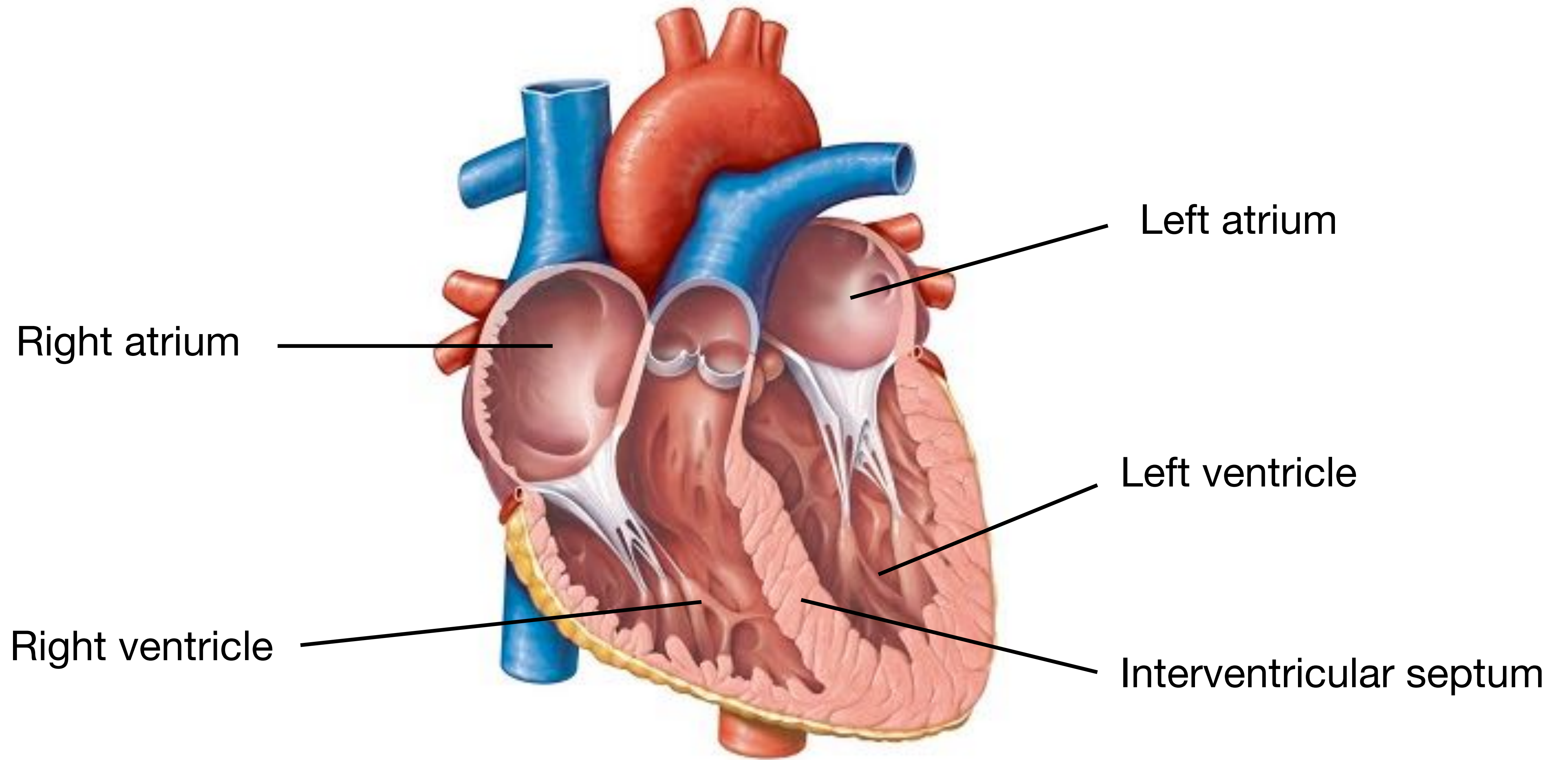
Atria contract

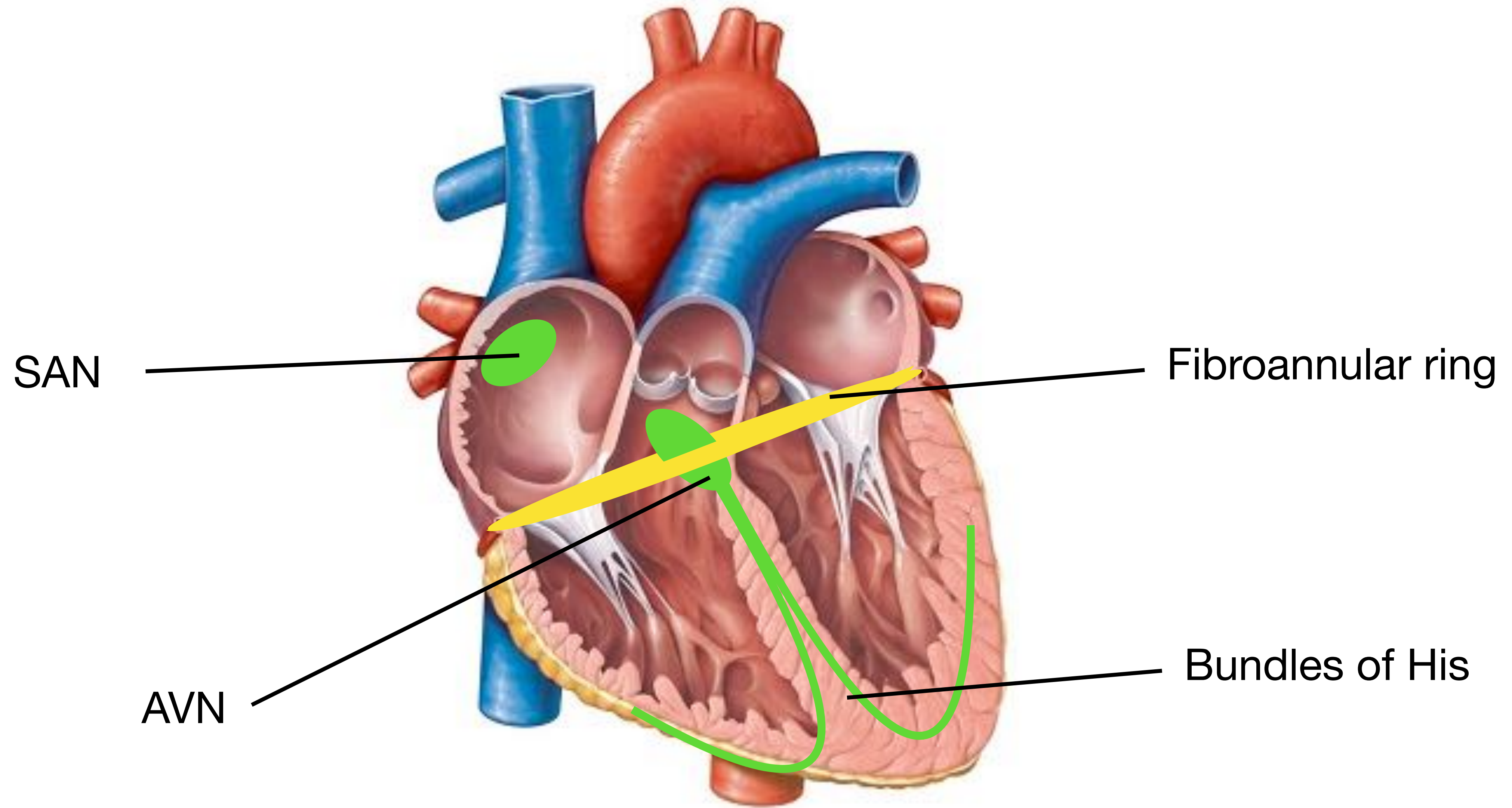


Short pause

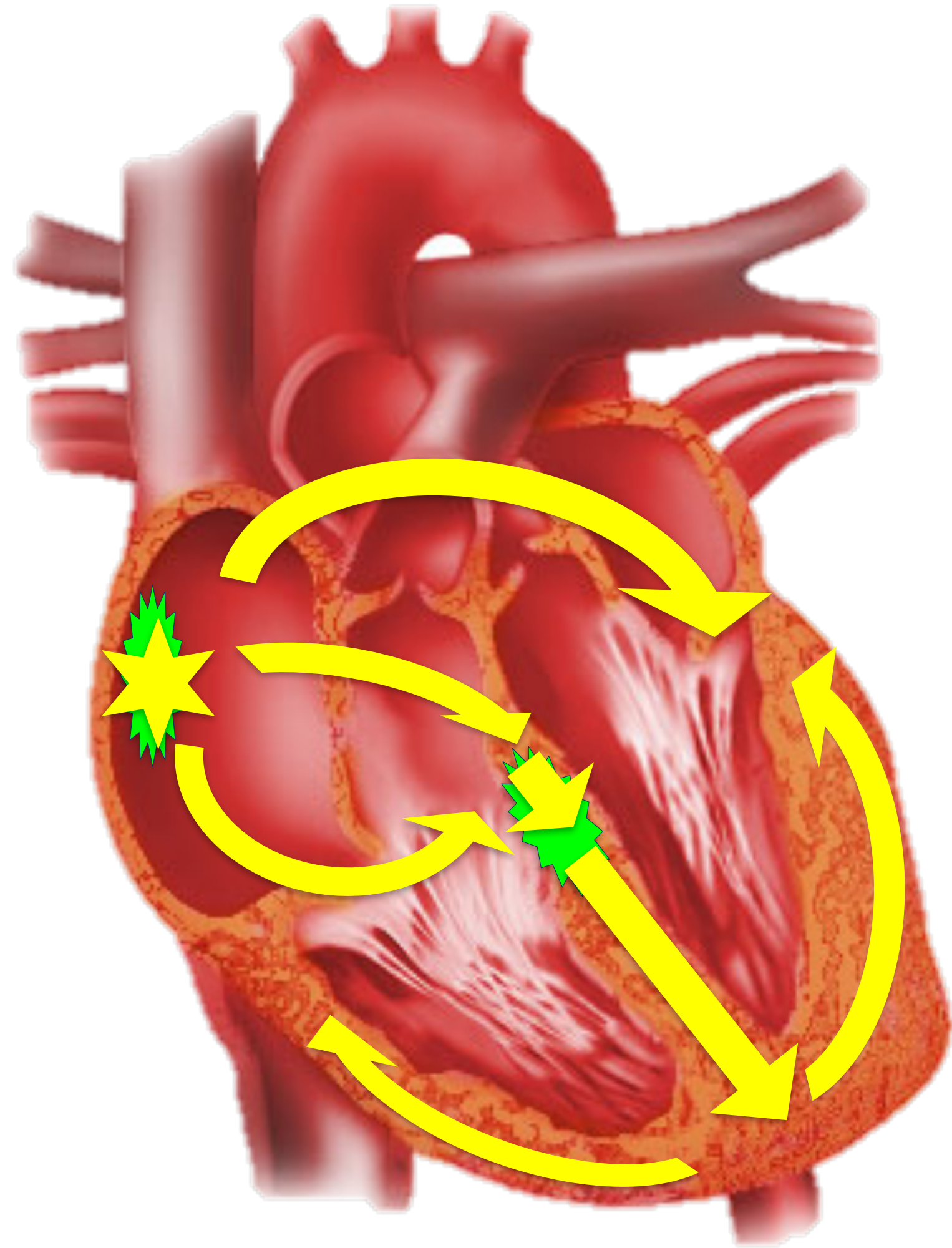


Ventricles contract

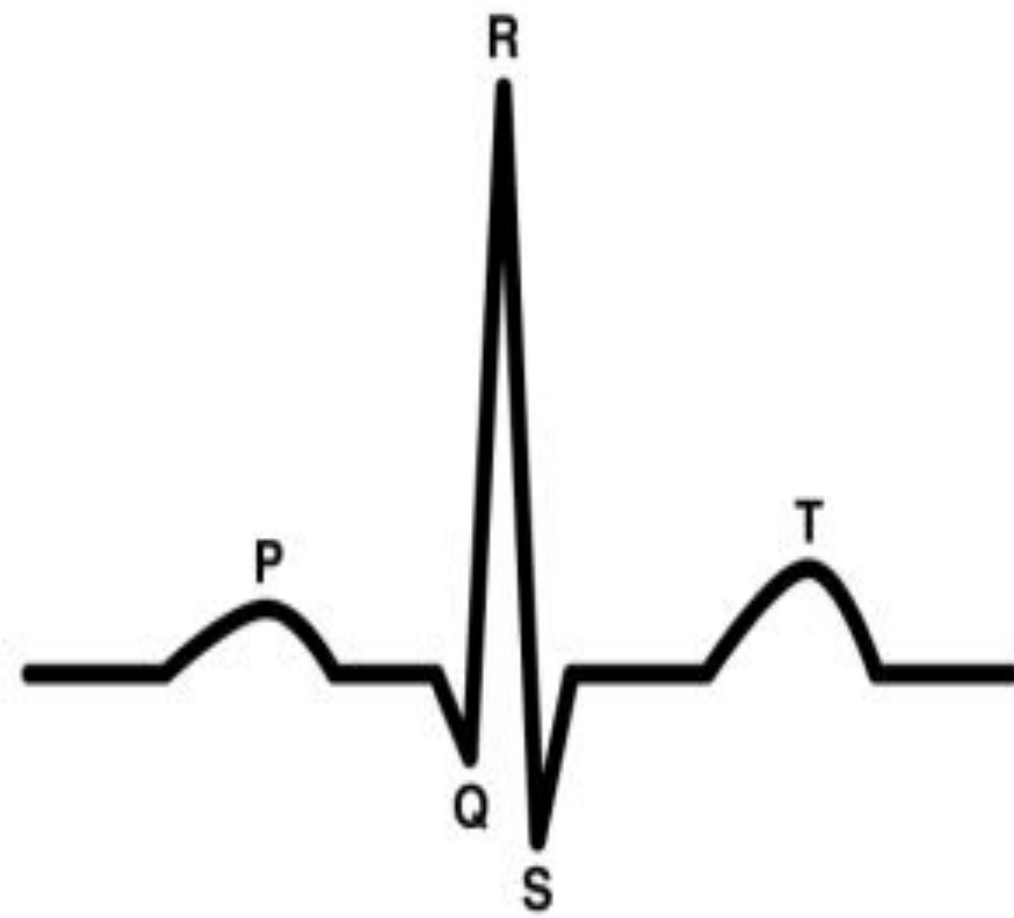




# THE ECG WAVEFORM



# THE ECG (SINUS) WAVEFORM



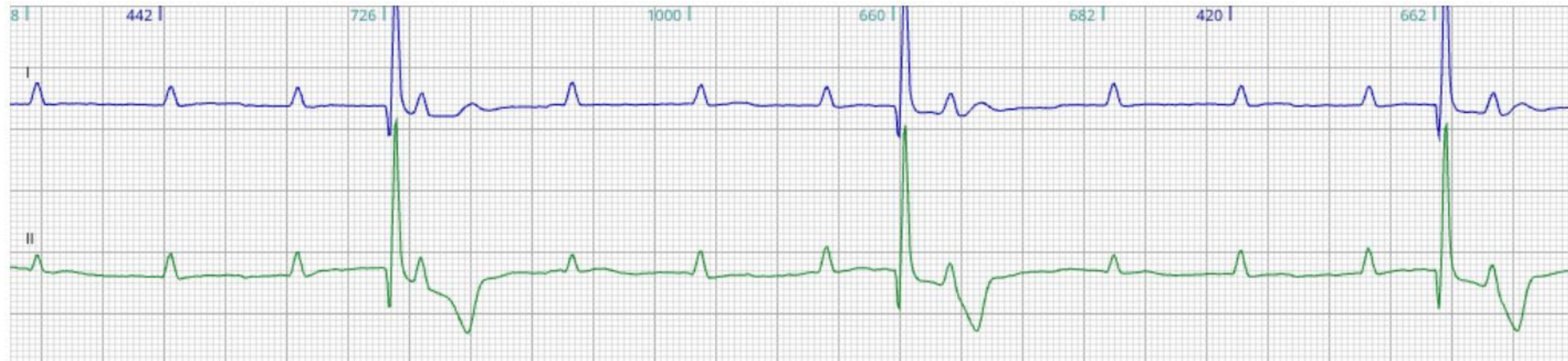**P wave:** Atrial depolarisation

**QRS complex:** Ventricular depolarisation

**T wave:** Ventricular repolarisation

Combined, this forms the sinus complex

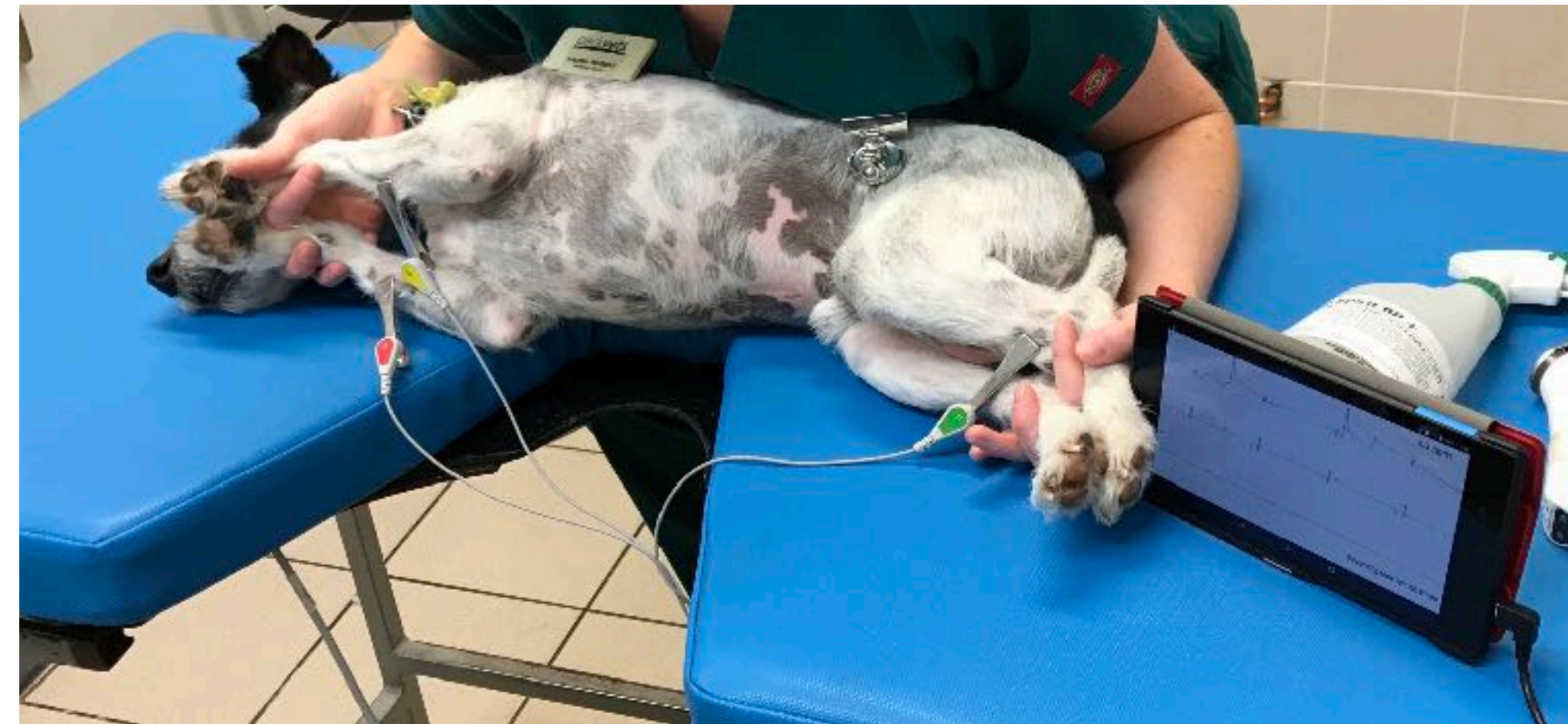
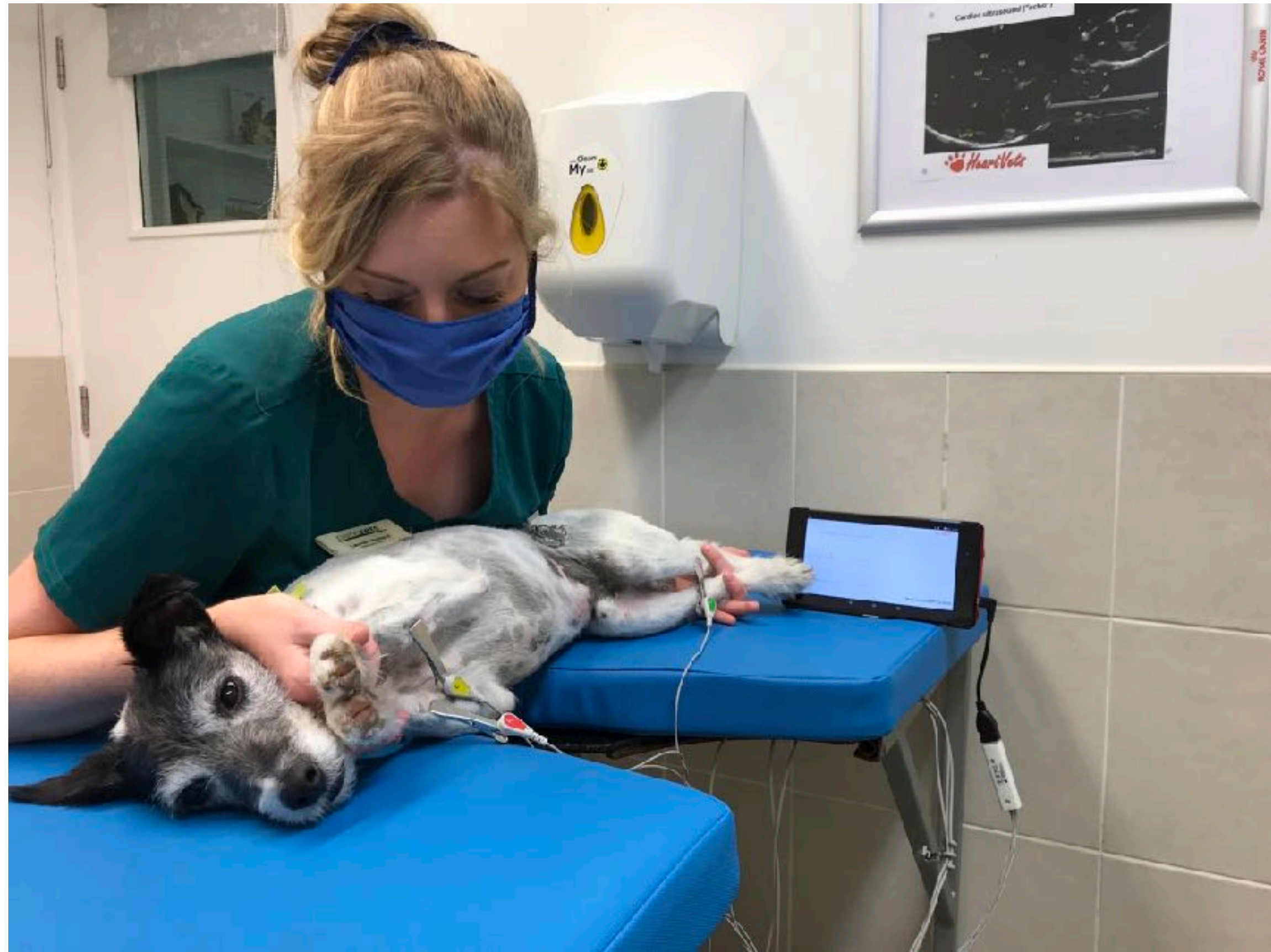# HOW TO RECORD AN ECG



An ECG is an electrical depiction of the change in cell (tissue) polarity during the cardiac cycle

The heart is a pump and in order to function, it needs to pump in a certain order to make sure blood flows in the right direction, at the right time, at the right speed.

# RECORDING AN ECG

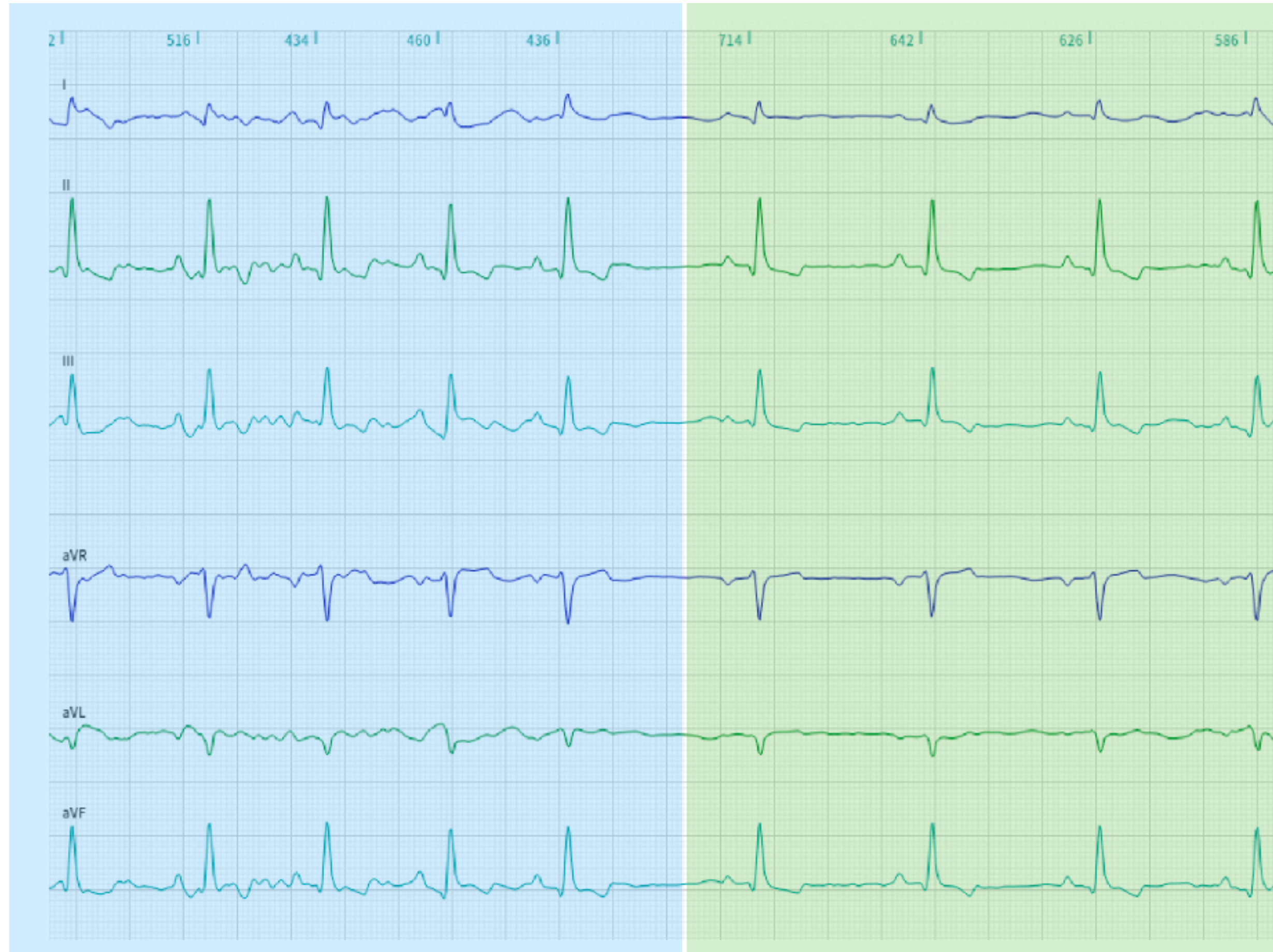

**Red to Right, Left to Lellow, Green Back Left,  
Black Back Right**

This gives us 3 (or actually 6) angles to look at the direction of travel.



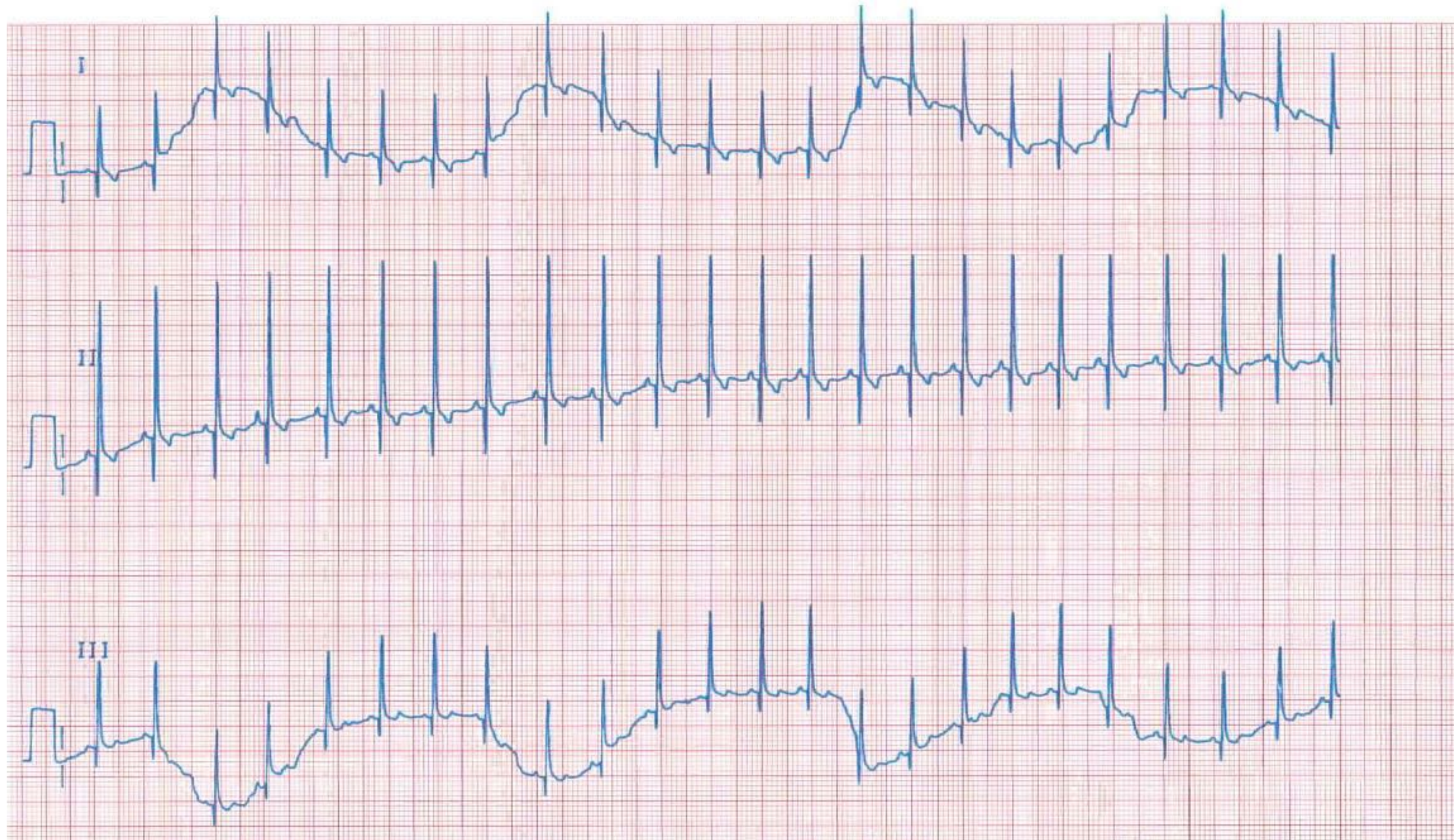
# MOVEMENT ARTEFACT



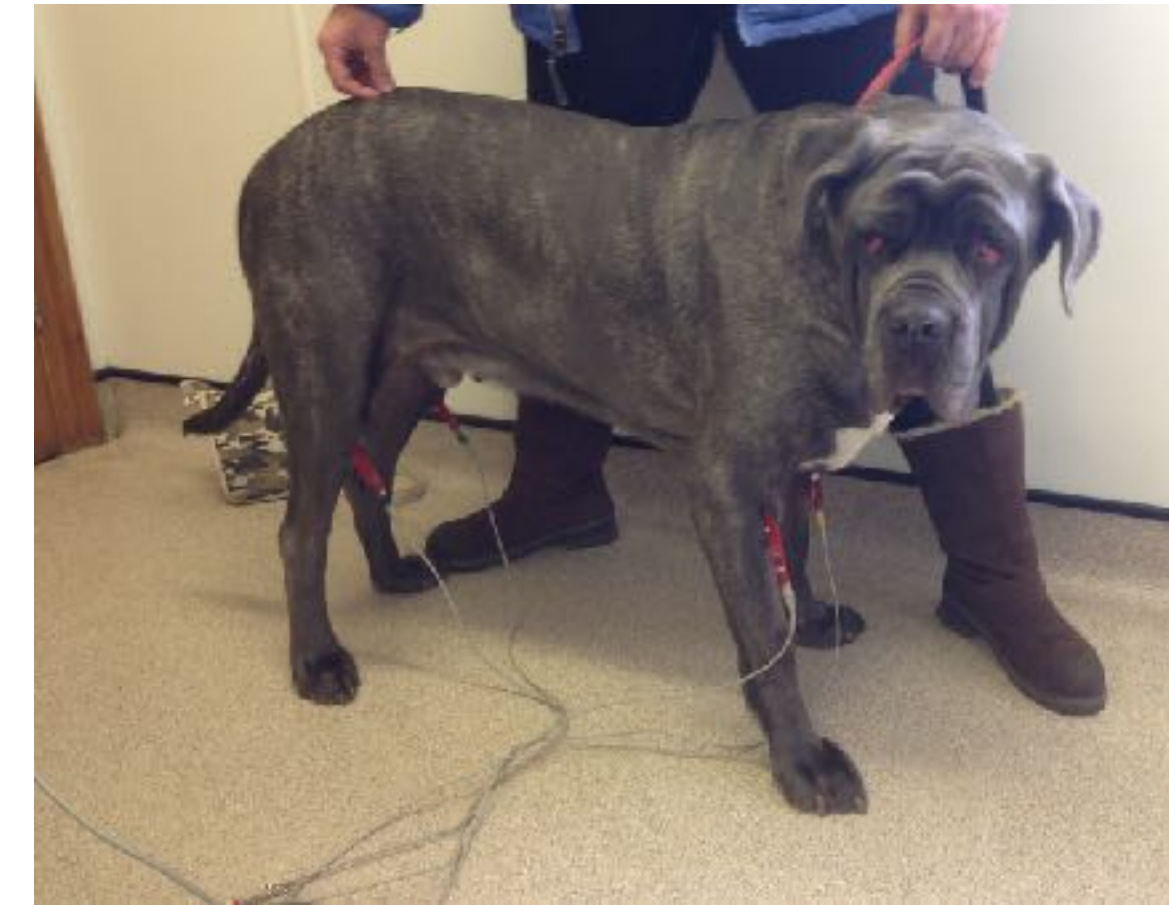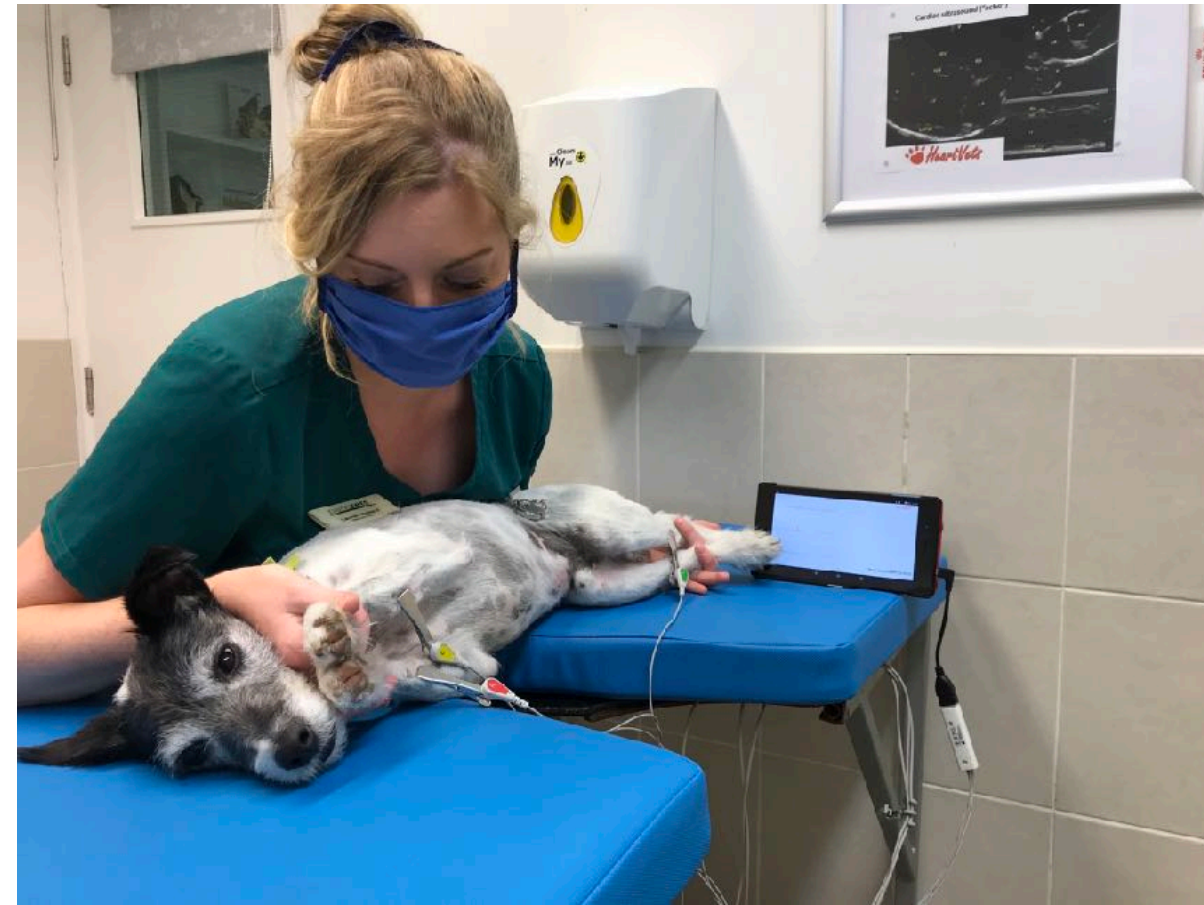Muscle tremor

Clean baseline

# MOVEMENT ARTEFACT



# ECG RULE NUMBER ONE



Keep the patient as still and relaxed as possible

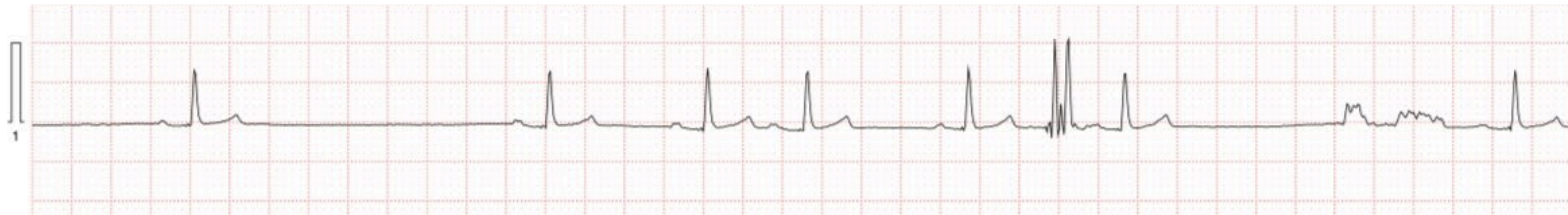Attach the electrodes to loose skin, somewhere well tolerated

Right lateral is preferable, but if the patient is happier in another position, record the ECG there

Minimise artefact by minimising patient movement


# ECG RULE NUMBER TWO

Record more than one lead (if you can) - do not rely on single channel ECGs

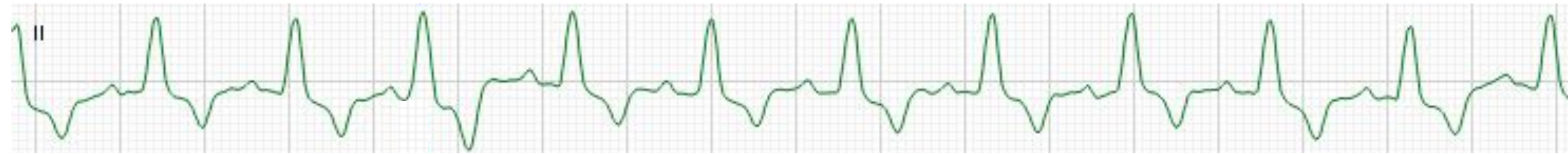

Make sure if you see something, you can see it on all the leads not just one

# IT'S ALWAYS BETTER TO RECORD MORE THAN ONE LEAD

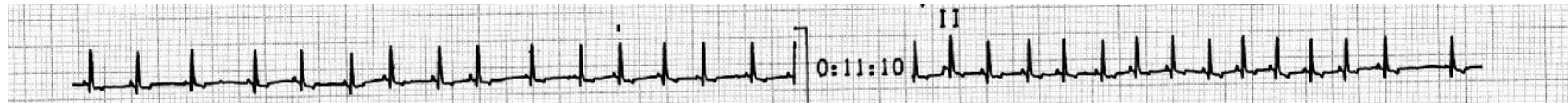


# IT'S ALWAYS BETTER TO RECORD MORE THAN ONE LEAD



# ECG RULE NUMBER THREE

Record lots of ECG



A person is shown swimming underwater, viewed from below. Their arms are outstretched horizontally, and they are looking upwards towards a bright light source, likely the sun, which creates a strong lens flare and illuminates the water with rays of light. The water is a deep blue color with visible ripples and reflections on the surface.

**“Trying to diagnose an intermittent arrhythmia on an ECG is like trying to catch a fish by swimming in the sea with your arms open wide”**

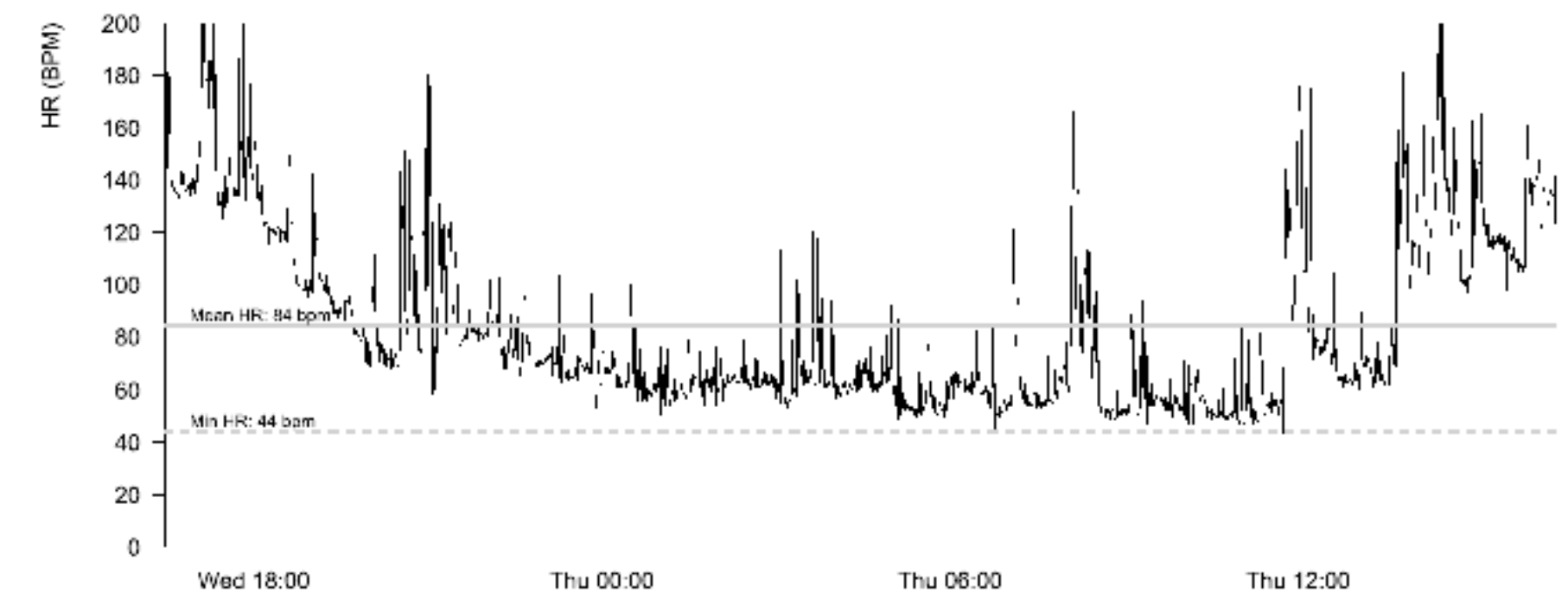
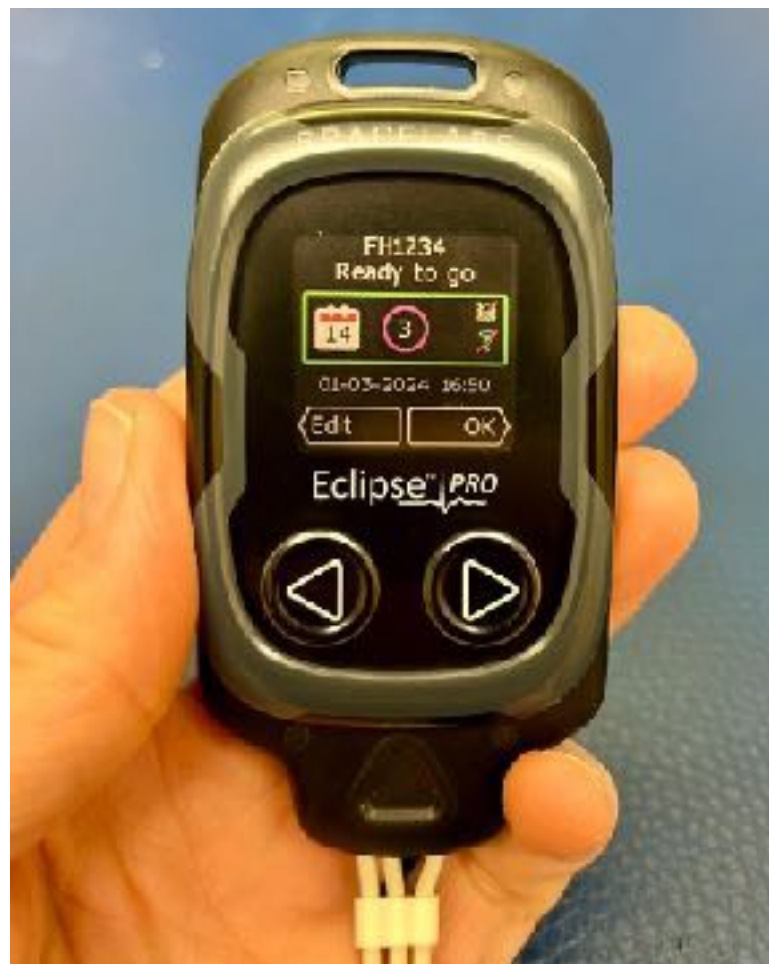Dr. Mark Patteson

# ECG RULE 3

Record lots of ECG

A 2-minute ECG represents a tiny fraction of the day

Record for longer - 24h or even 48h (or longer) if possible



# THE ECG RULES SO FAR

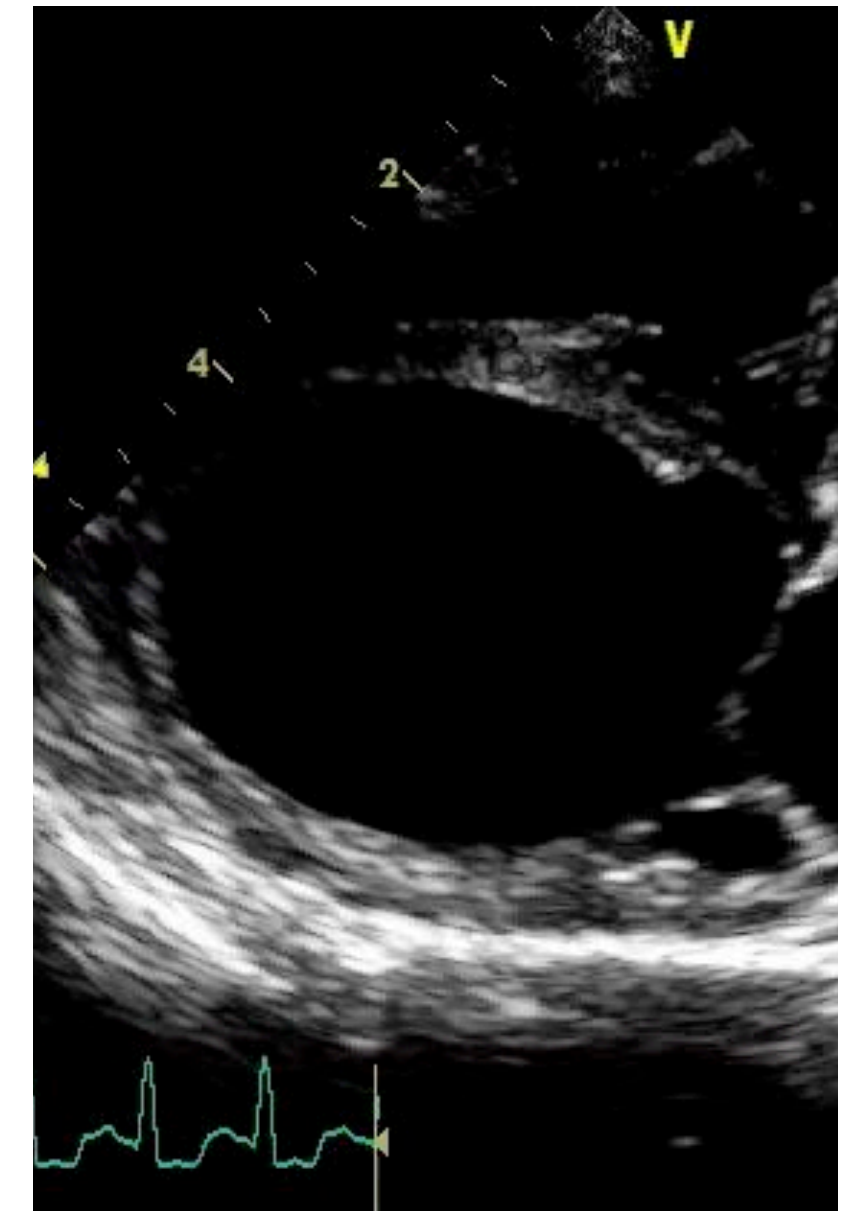

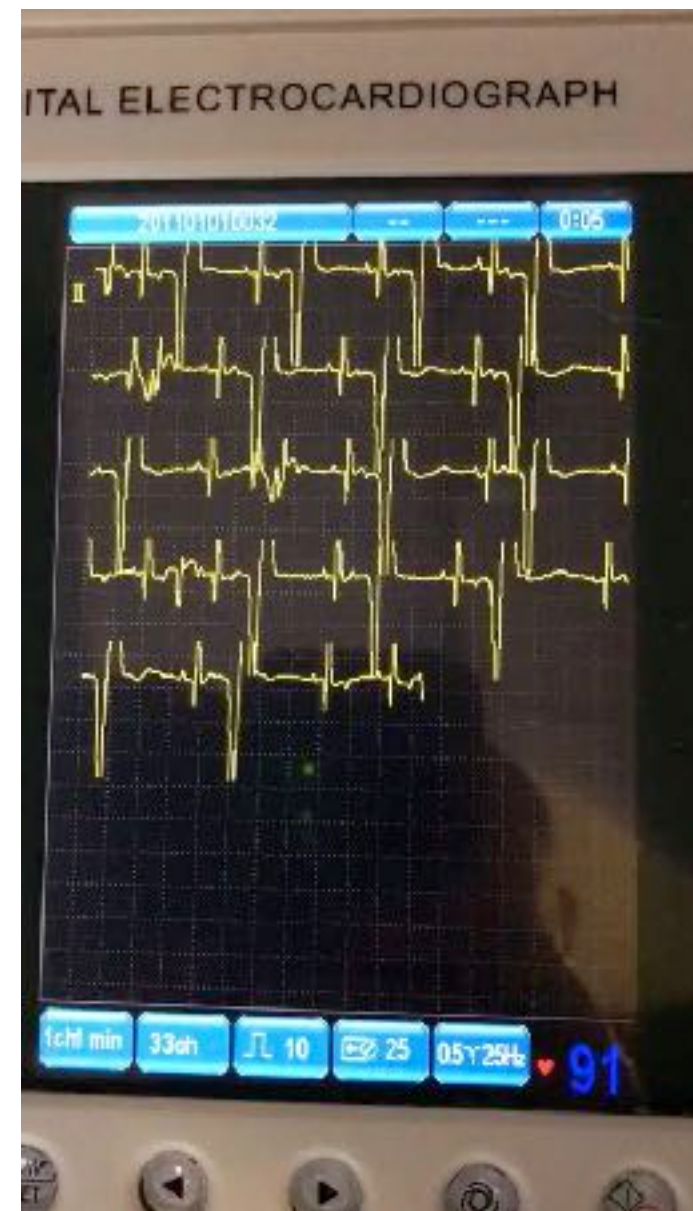
**Rule 1: Movement to Minimum:** patient relaxed, electrodes comfortable, patient still

**Rule 2: As many leads as possible:** record more than one lead (3 absolute minimum)

**Rule 3: Some is good; more is better:** record plenty of trace



# WHEN TO RECORD AN ECG

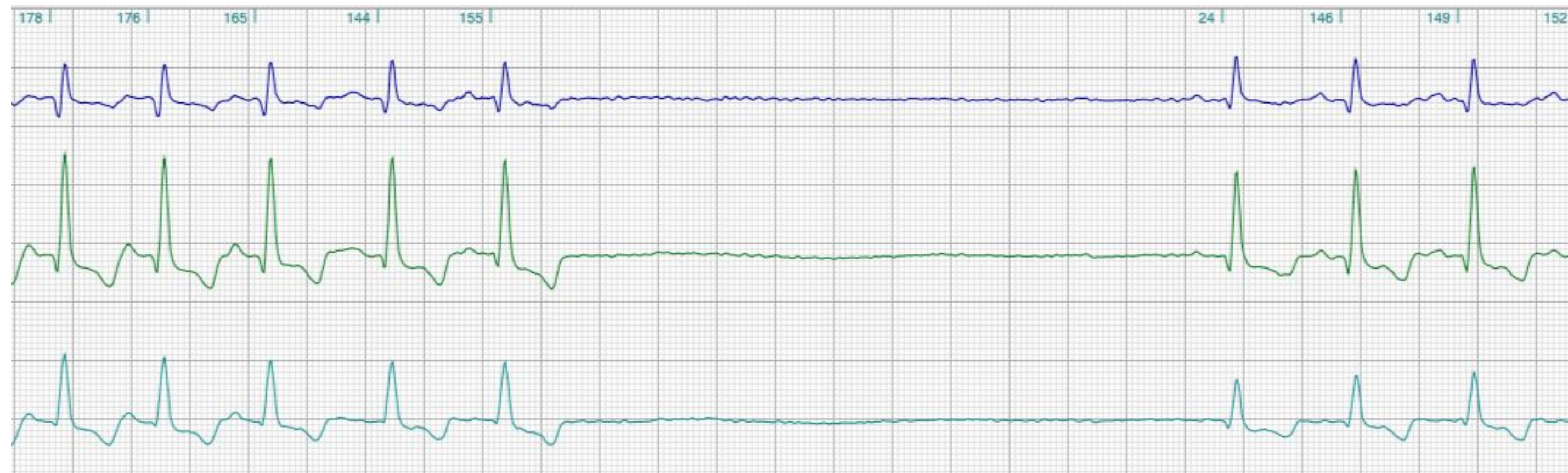


# ECG RULE 4

## Record an ECG if:

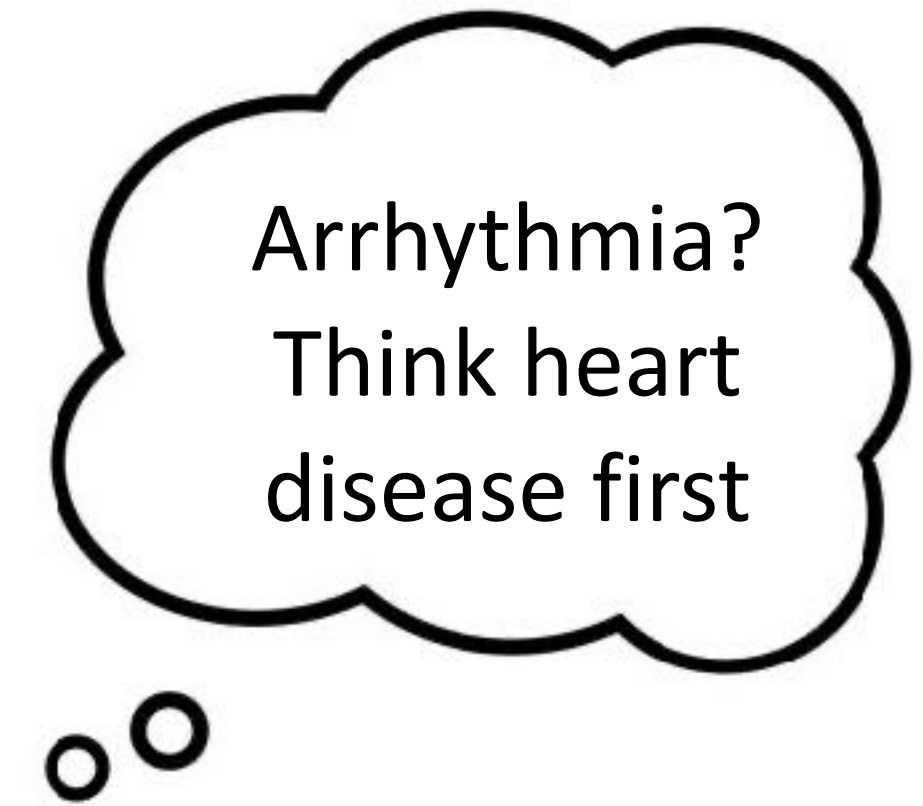
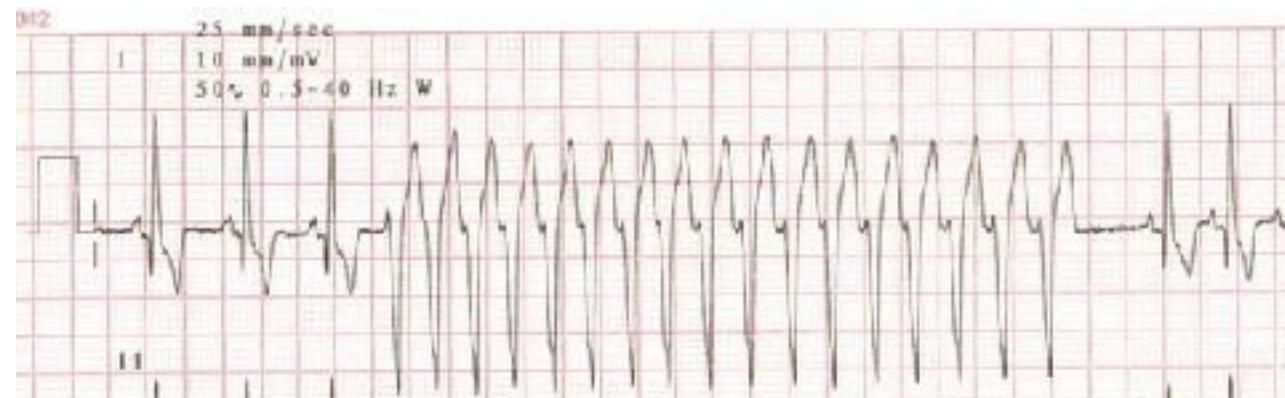

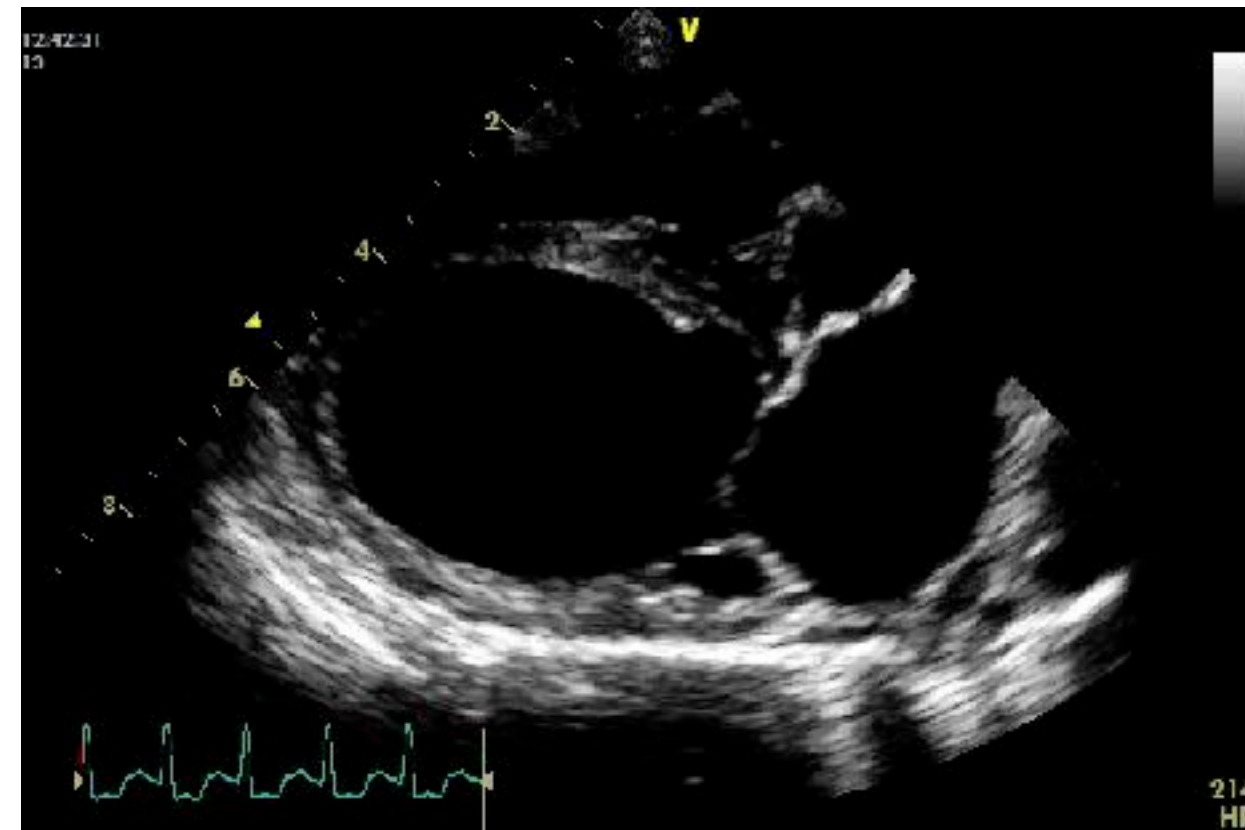
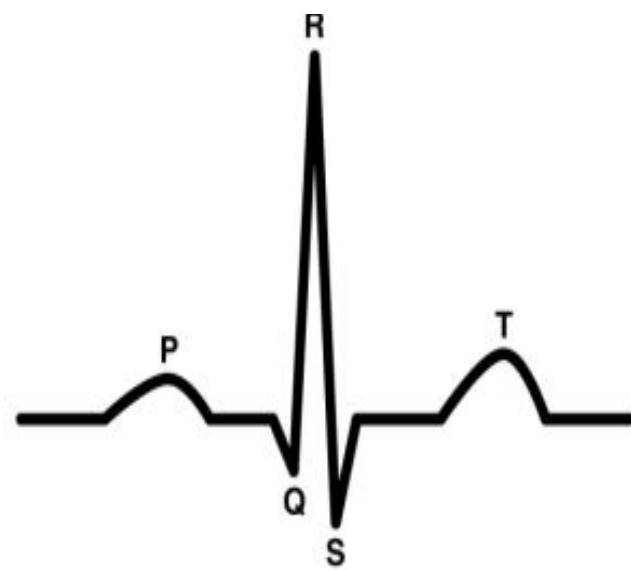
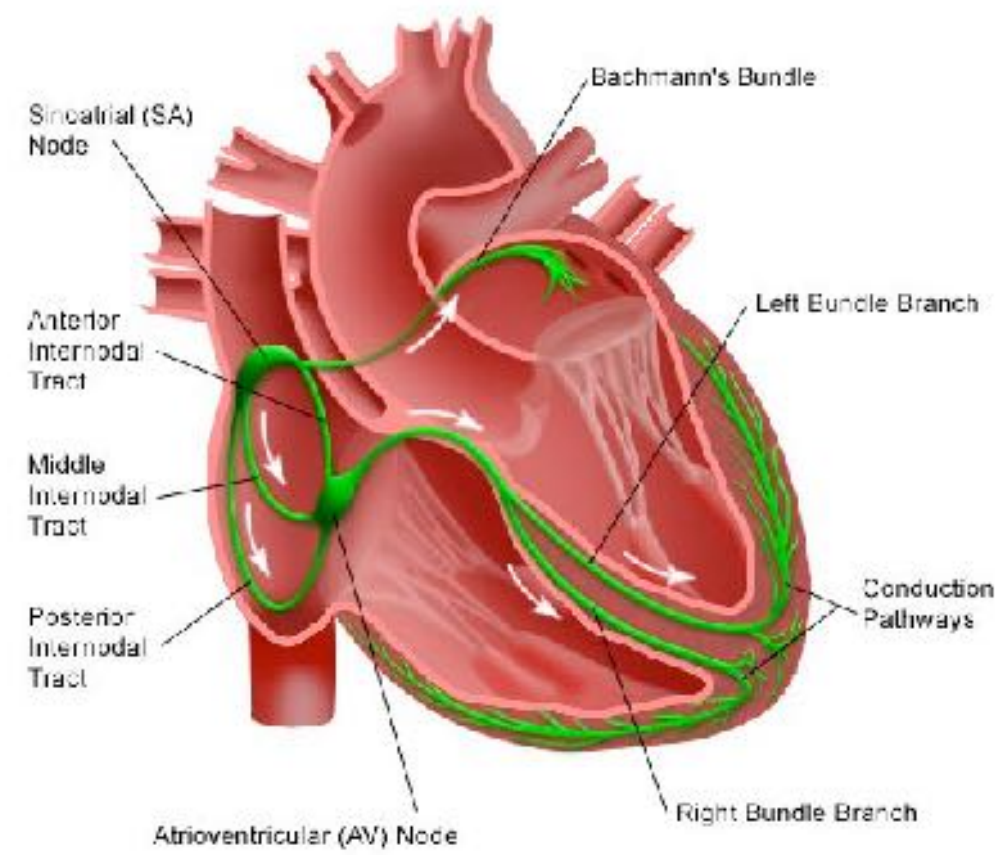
- a) You hear or see something abnormal
- b) The heart rate is too fast or too slow
- c) The patient is collapsing
- d) As part of a detailed cardiac investigation

# I'VE RECORDED A DIAGNOSTIC ECG



**WHAT NOW??!**

# UNDERSTANDING WHY ARRHYTHMIAS OCCUR IS HARDEST OF ALL



**COMMON THINGS ARE COMMON**

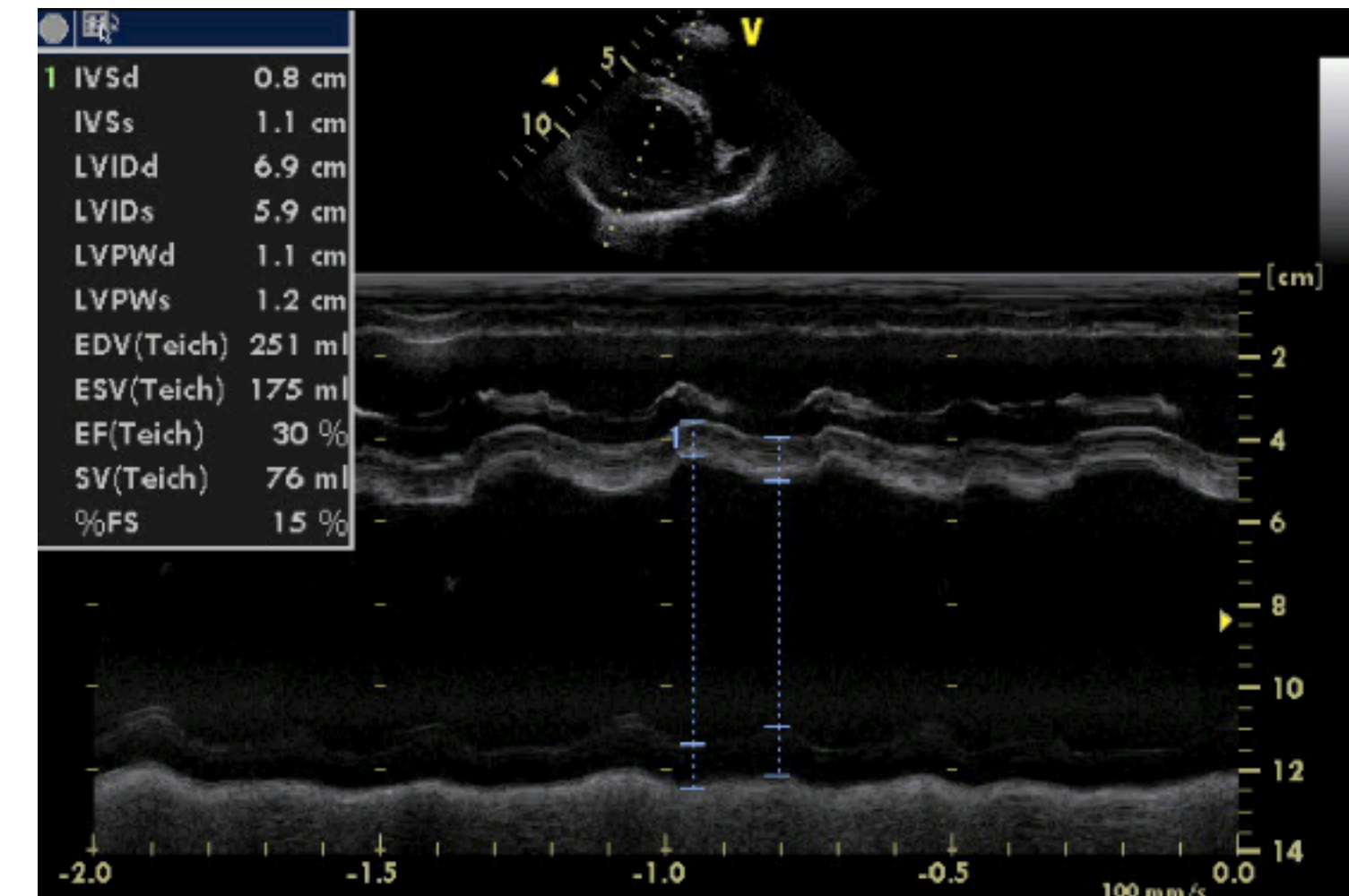
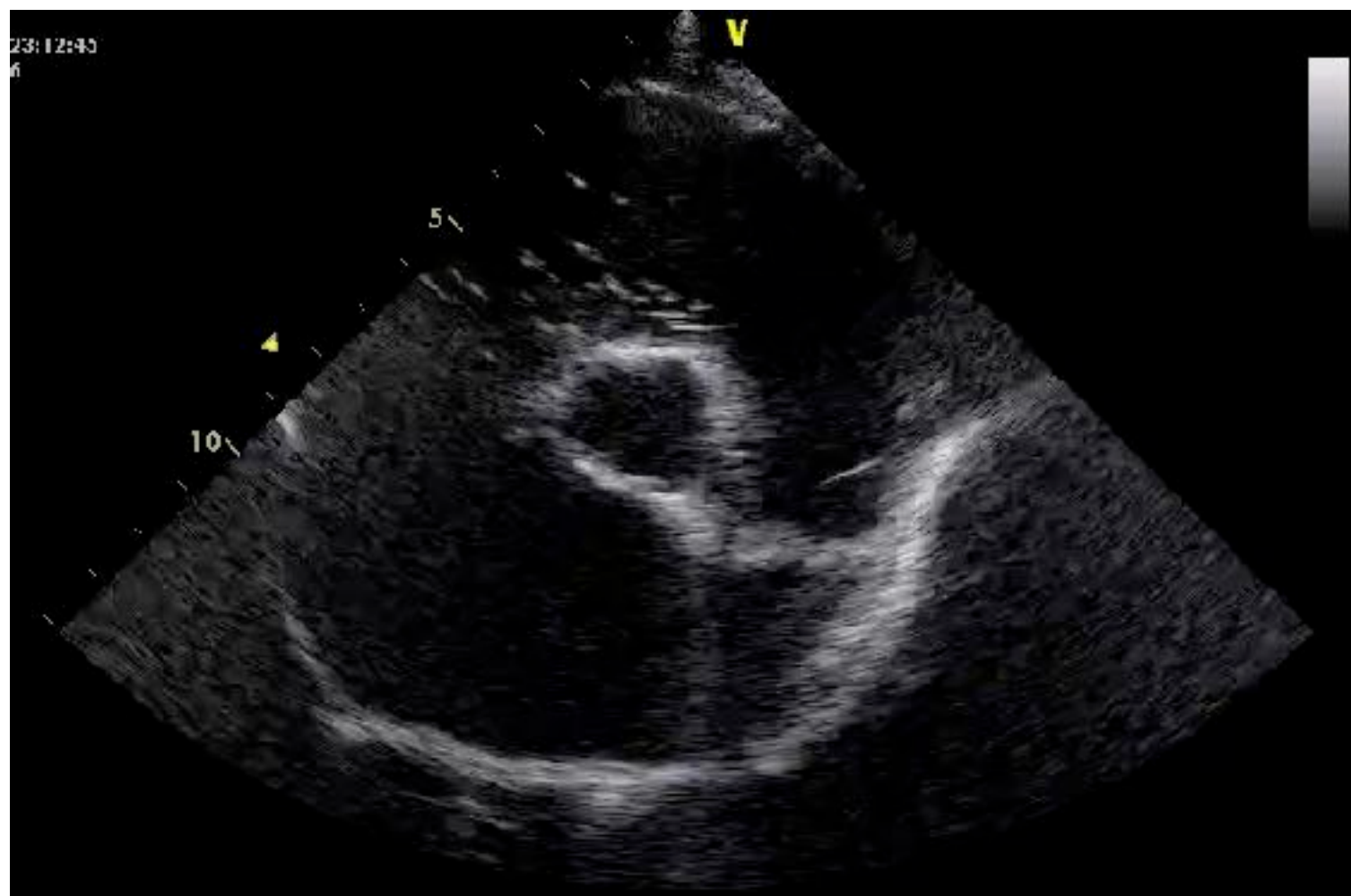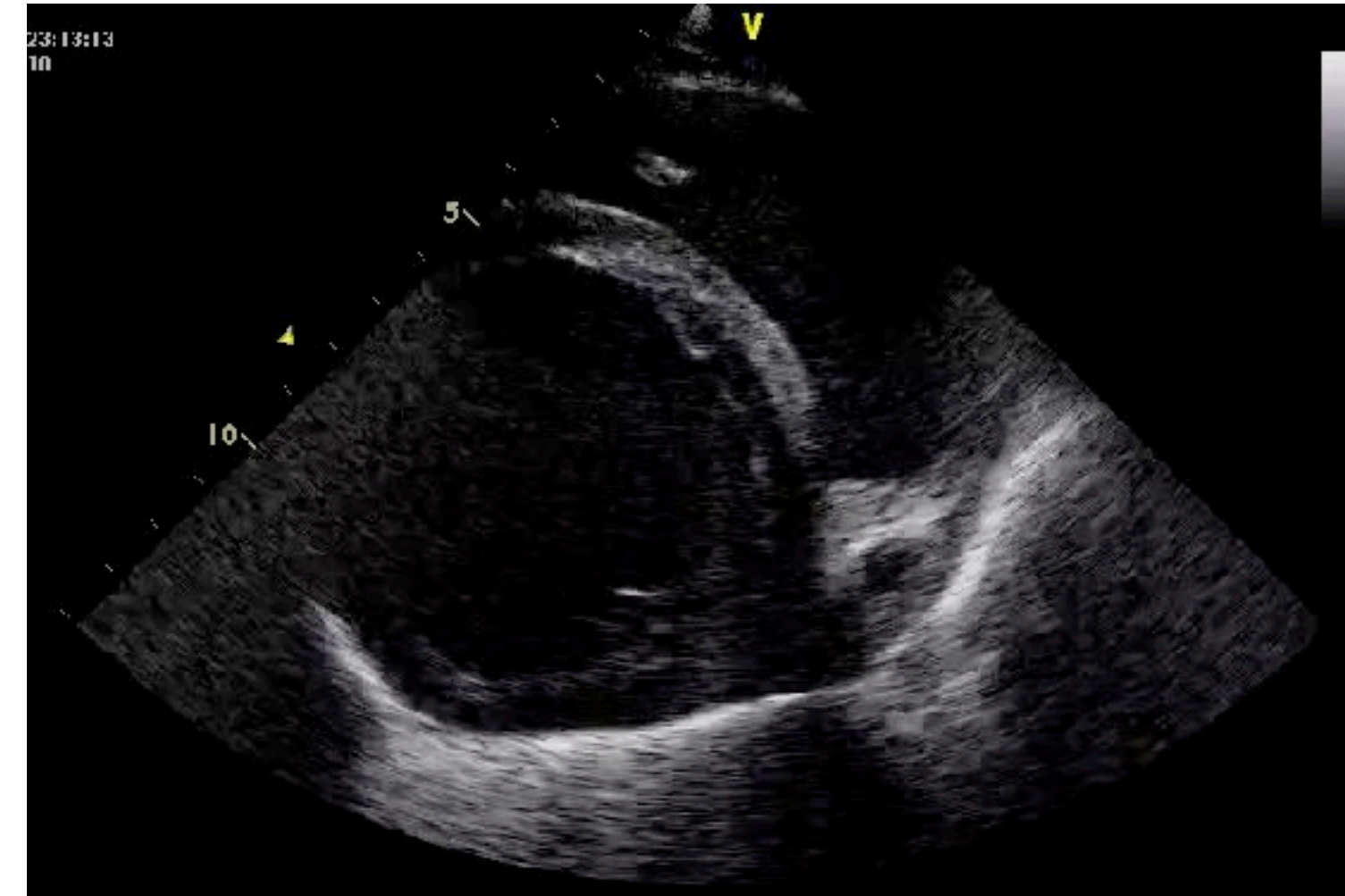
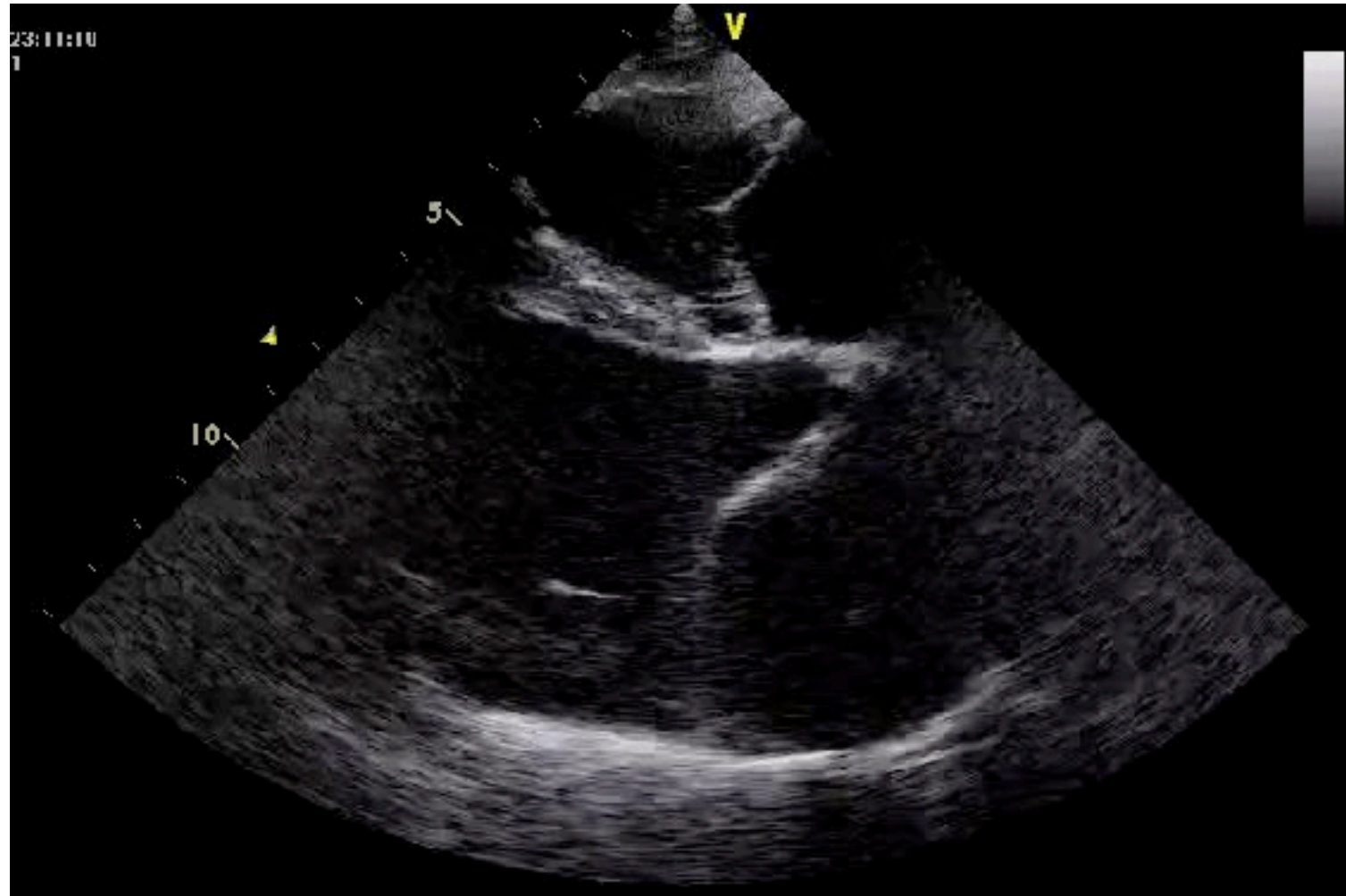
**COMMON CARDIAC CHANGES CAUSE COMMON ECG CHANGES**

**COMMON SYSTEMIC ILLNESSES CAUSE ECG CHANGES**

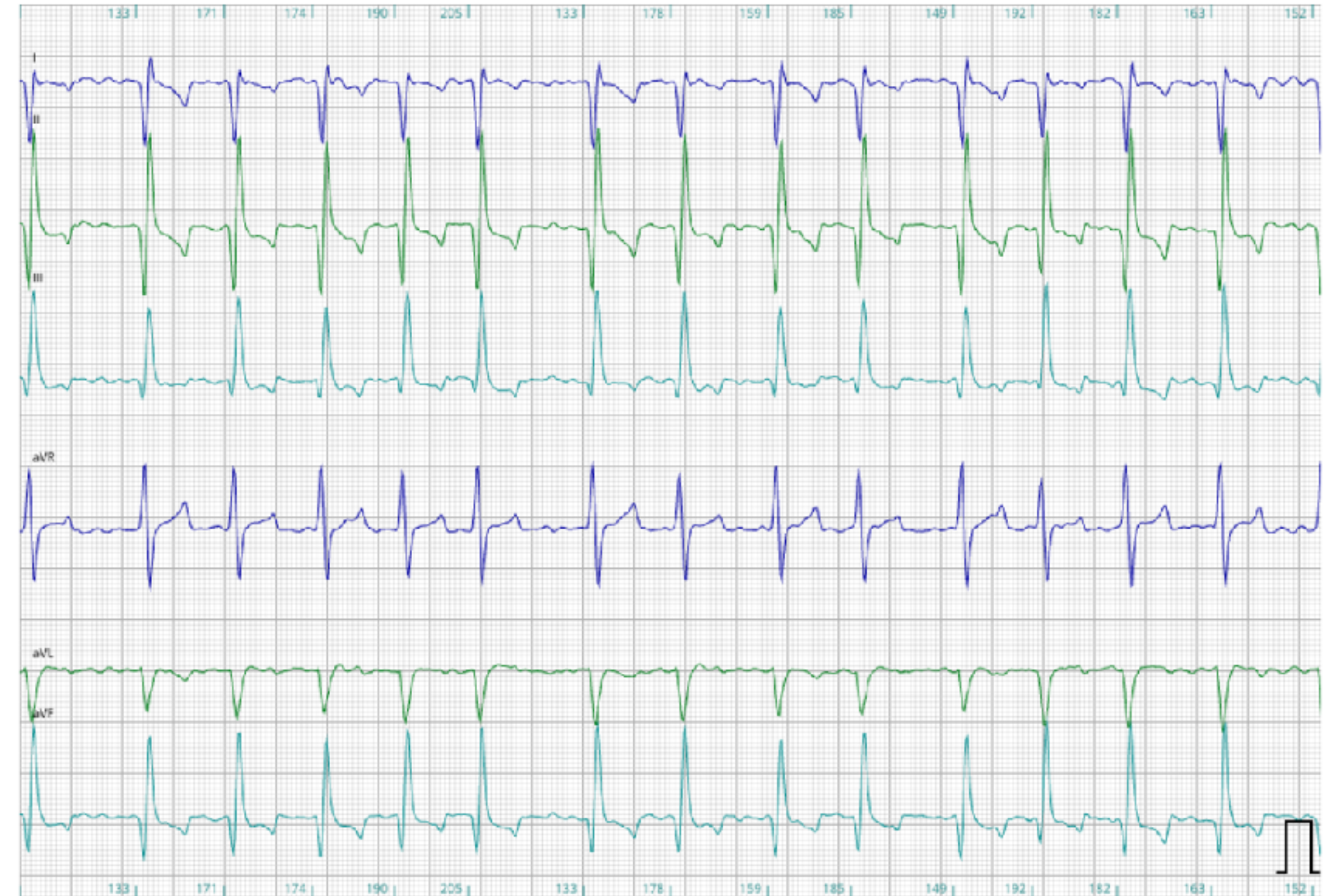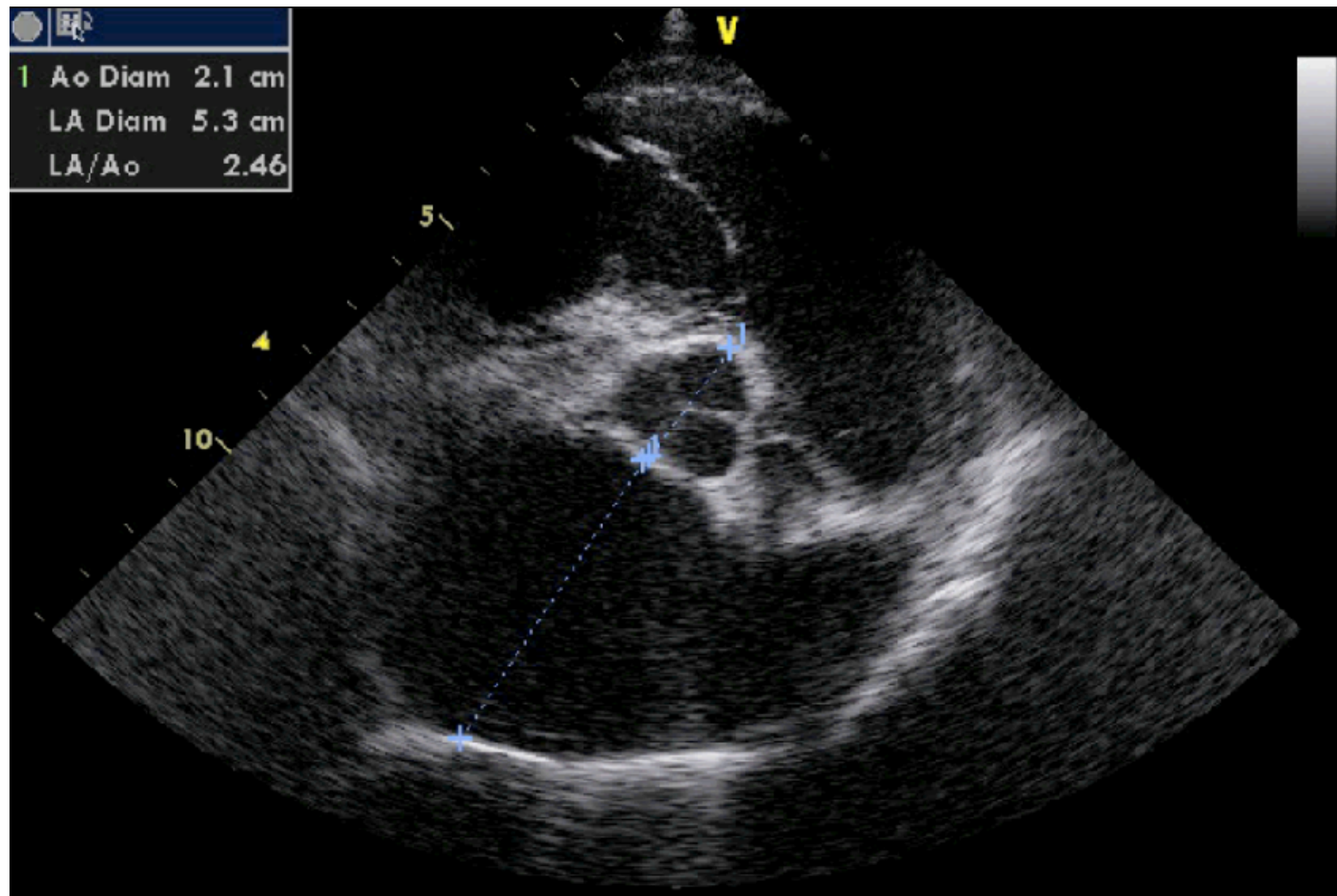
**SOME BREEDS GET SPECIFIC ARRHYTHMIAS**



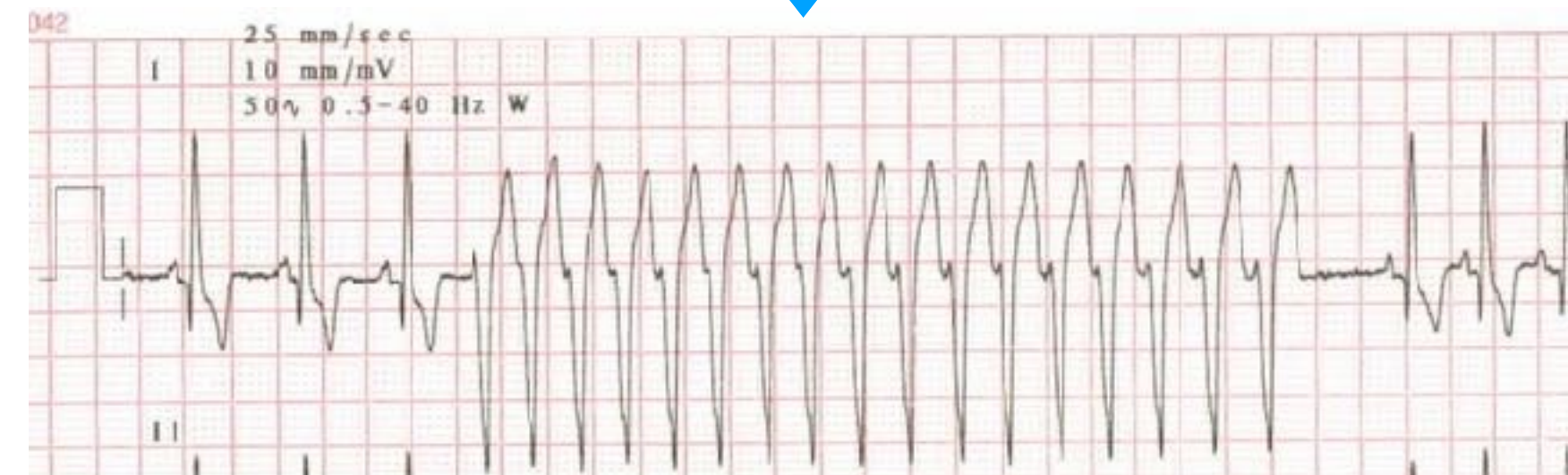

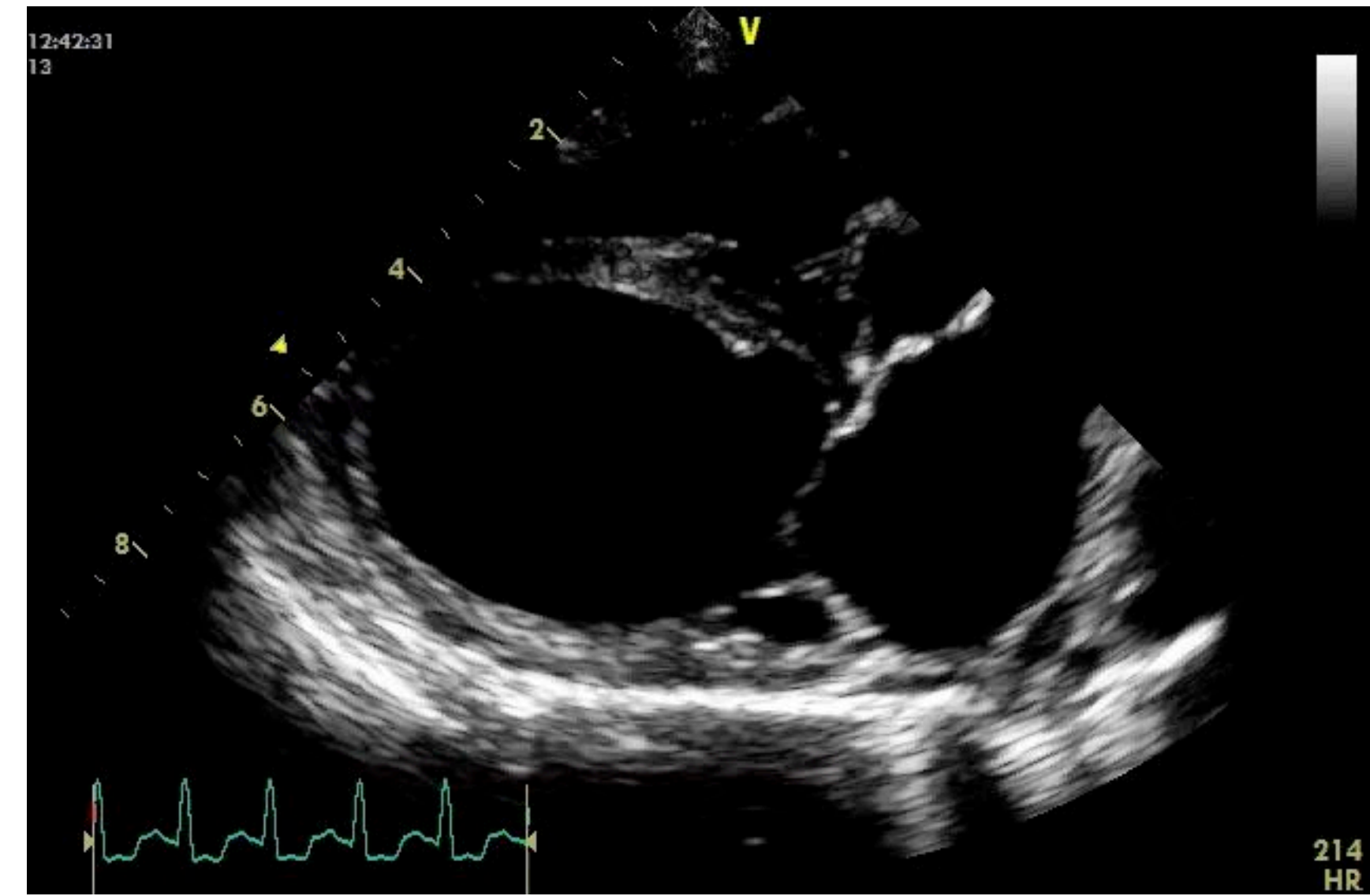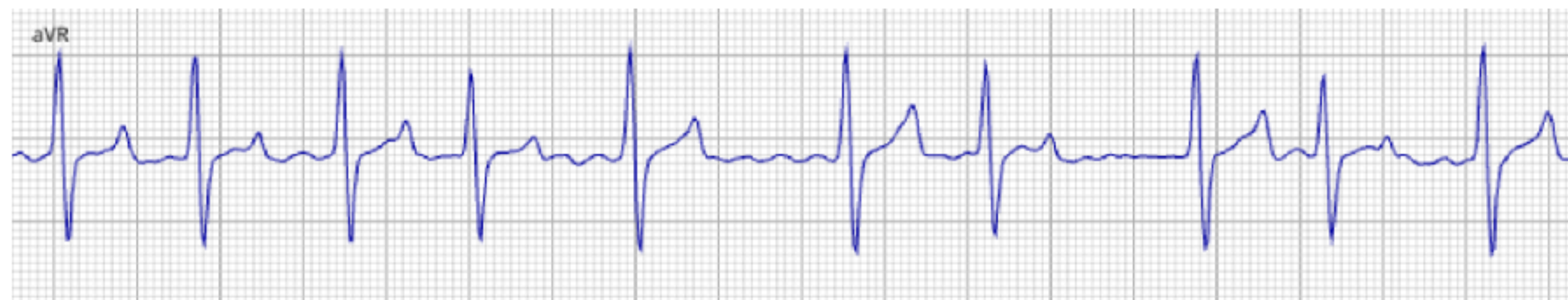

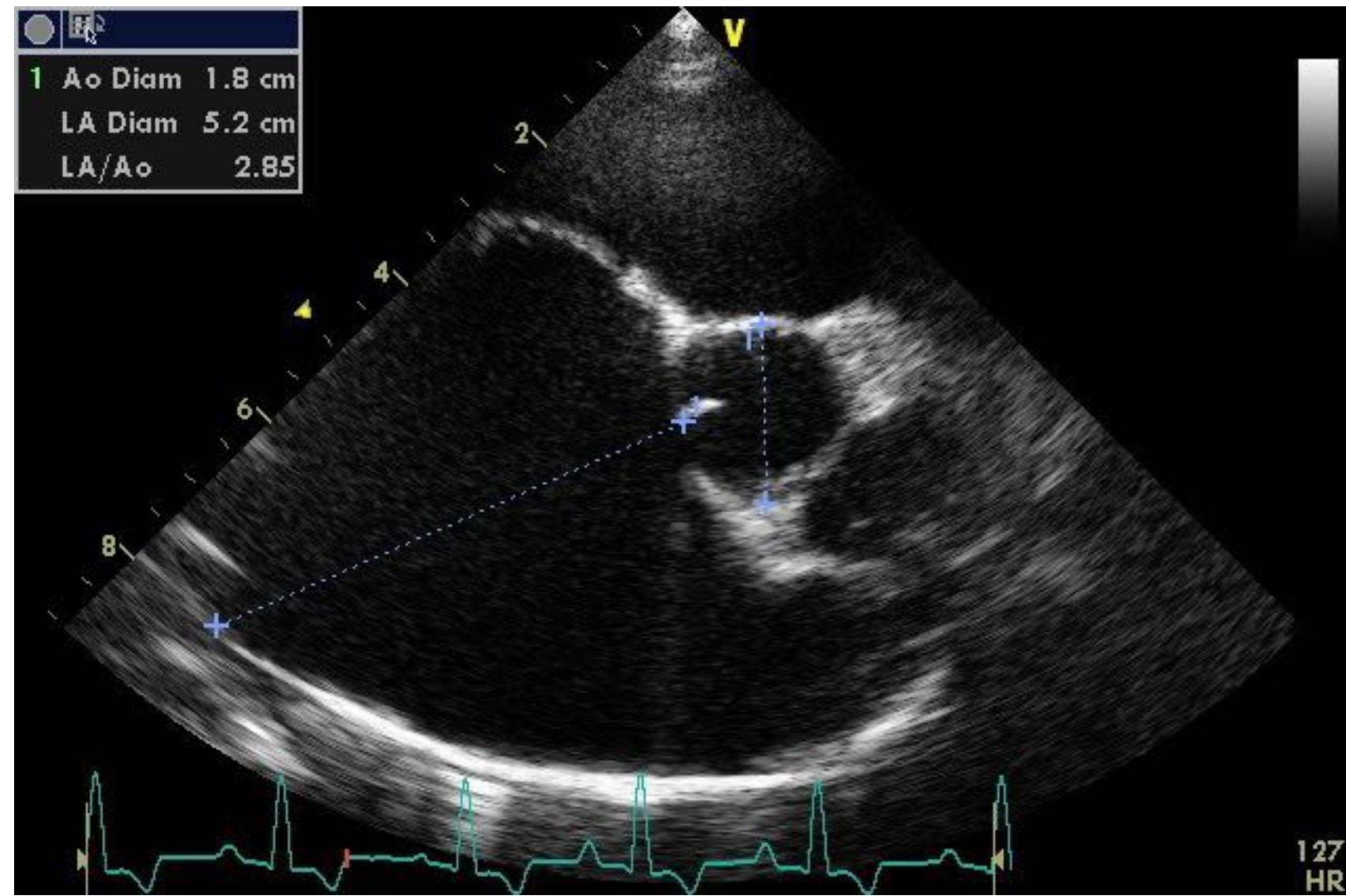
# COMMON THINGS ARE COMMON



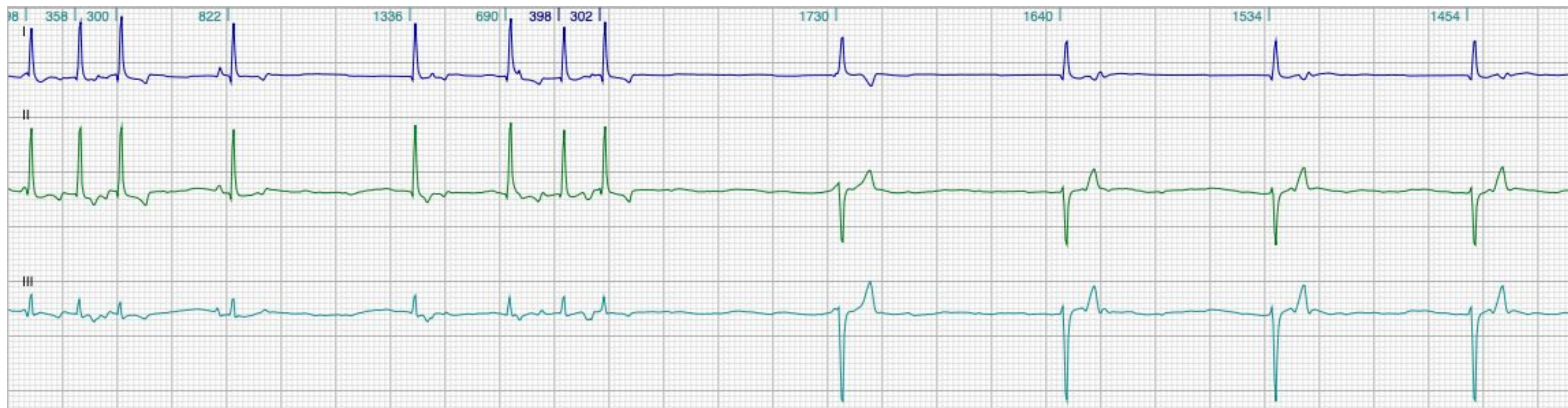# A BIG LEFT ATRIUM CAUSES AF

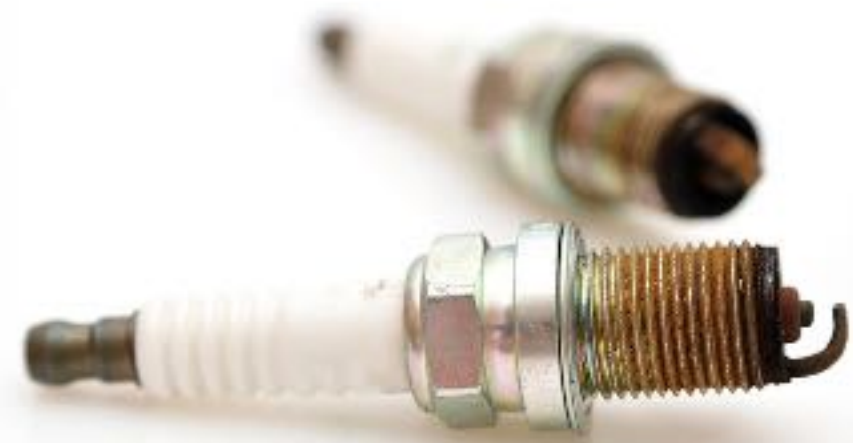

# COMMON THINGS ARE COMMON

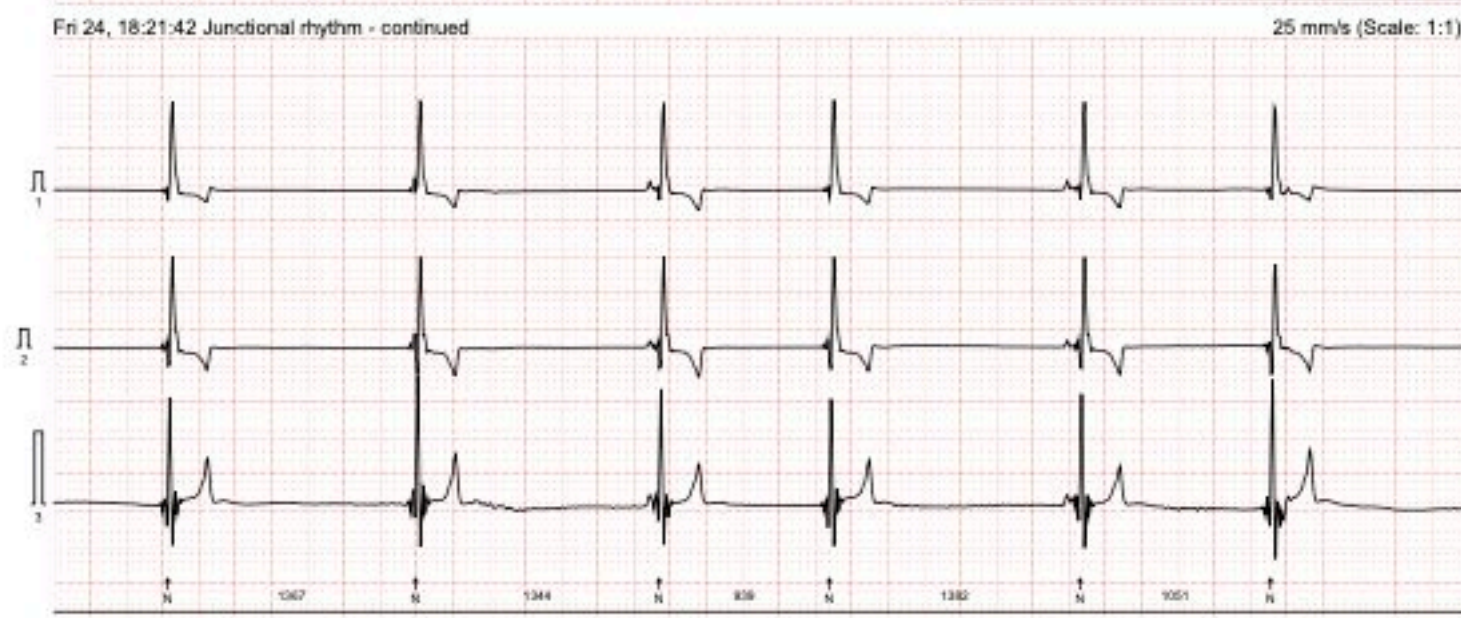
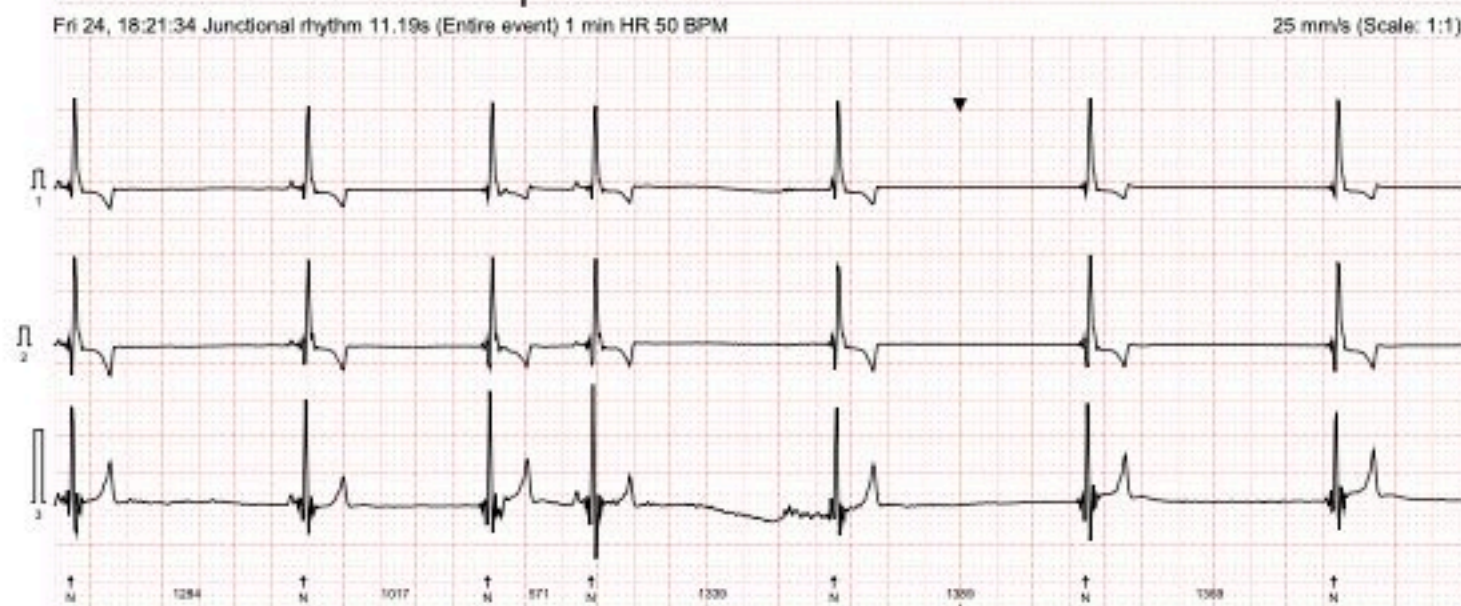
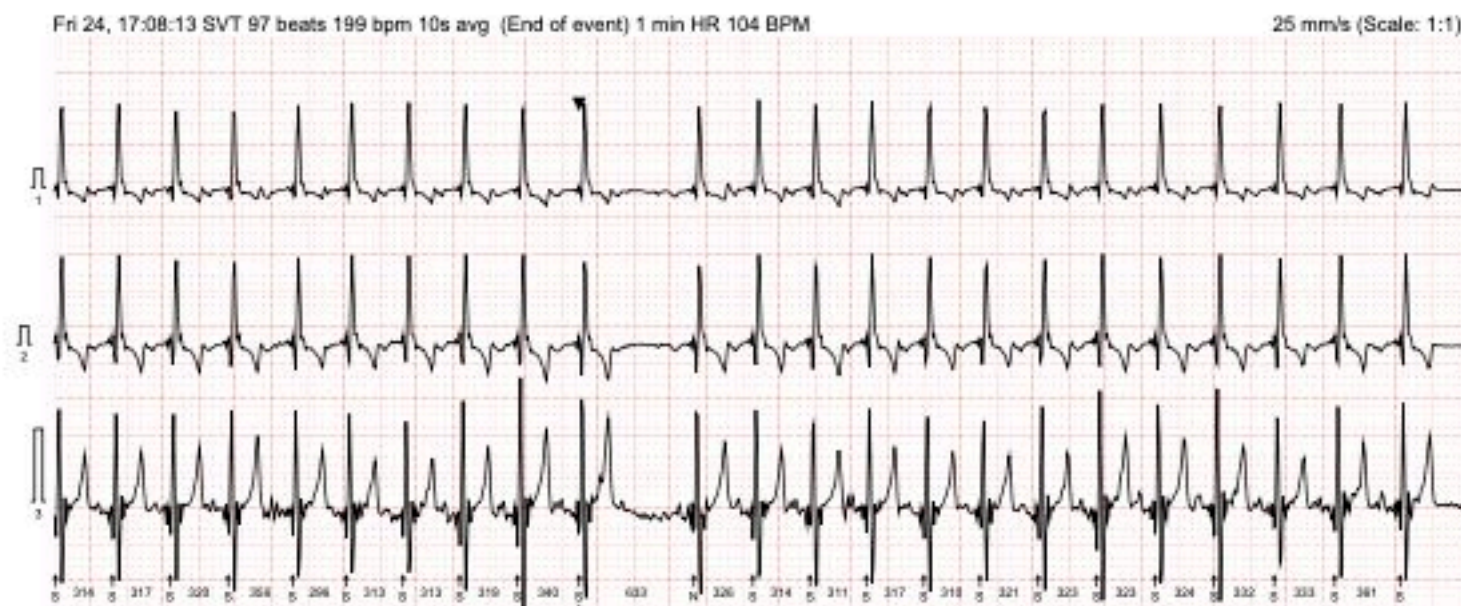
# 11yo Min Schnauzer, collapsing

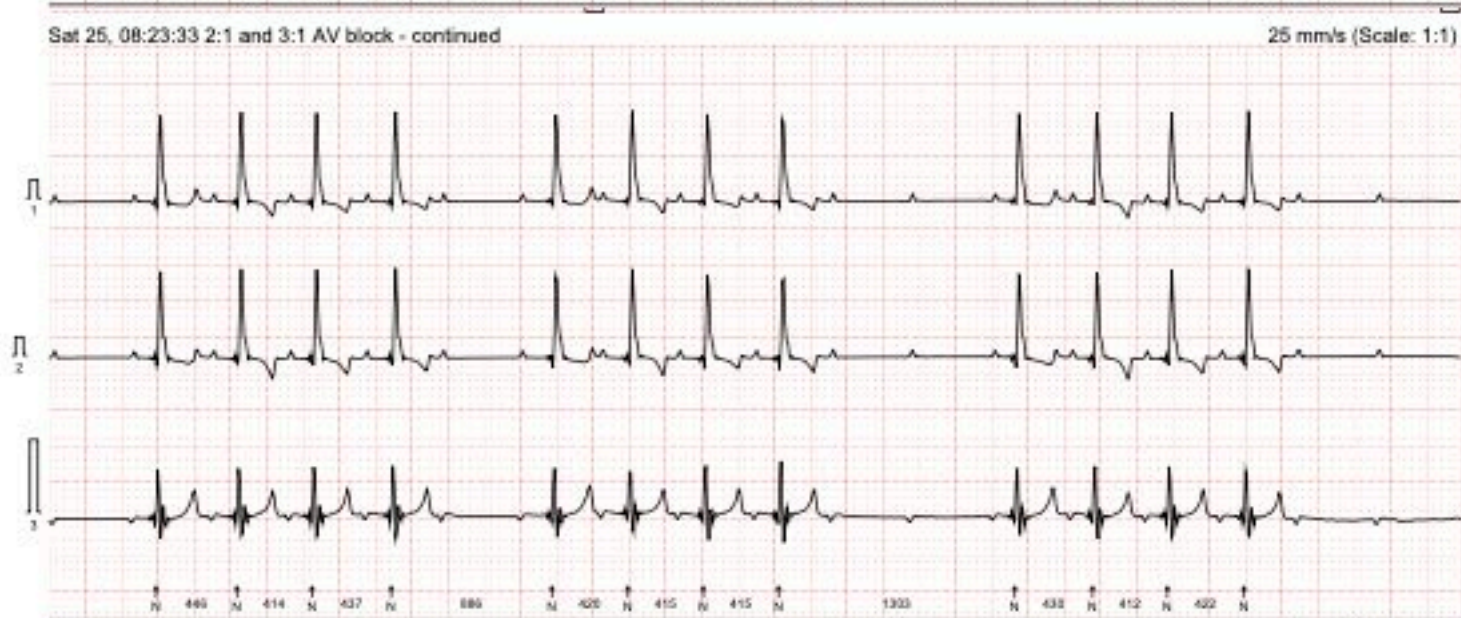
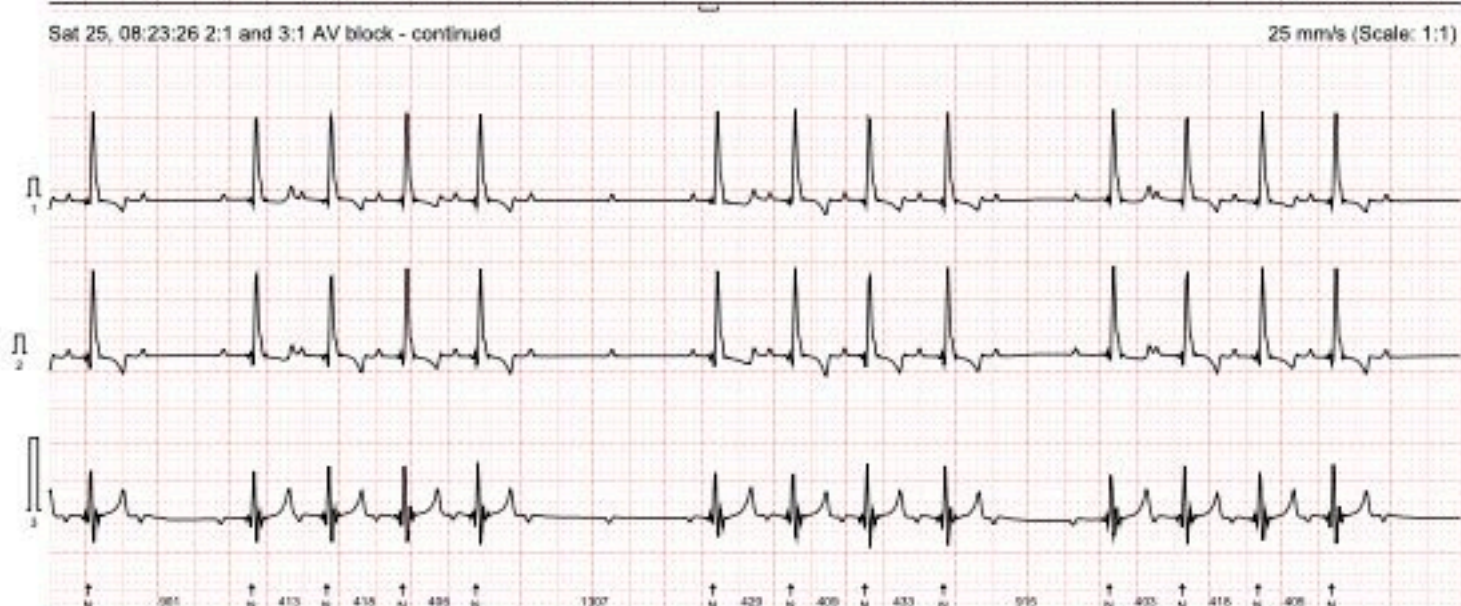
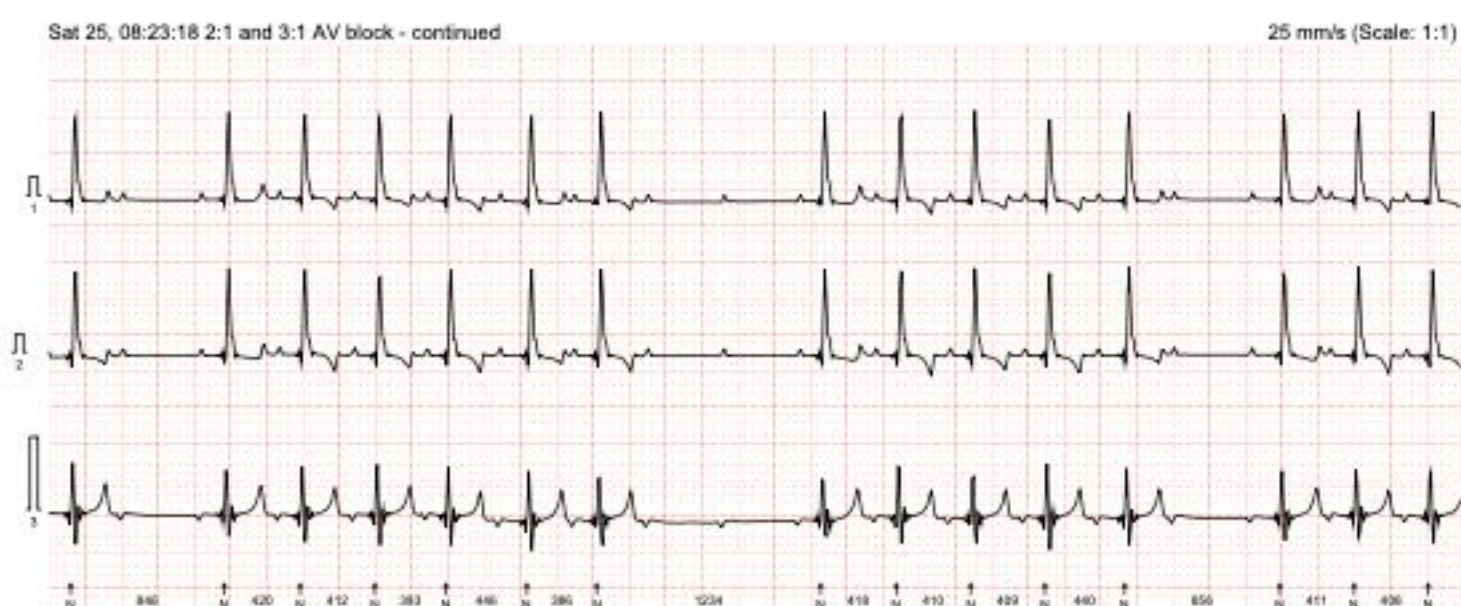

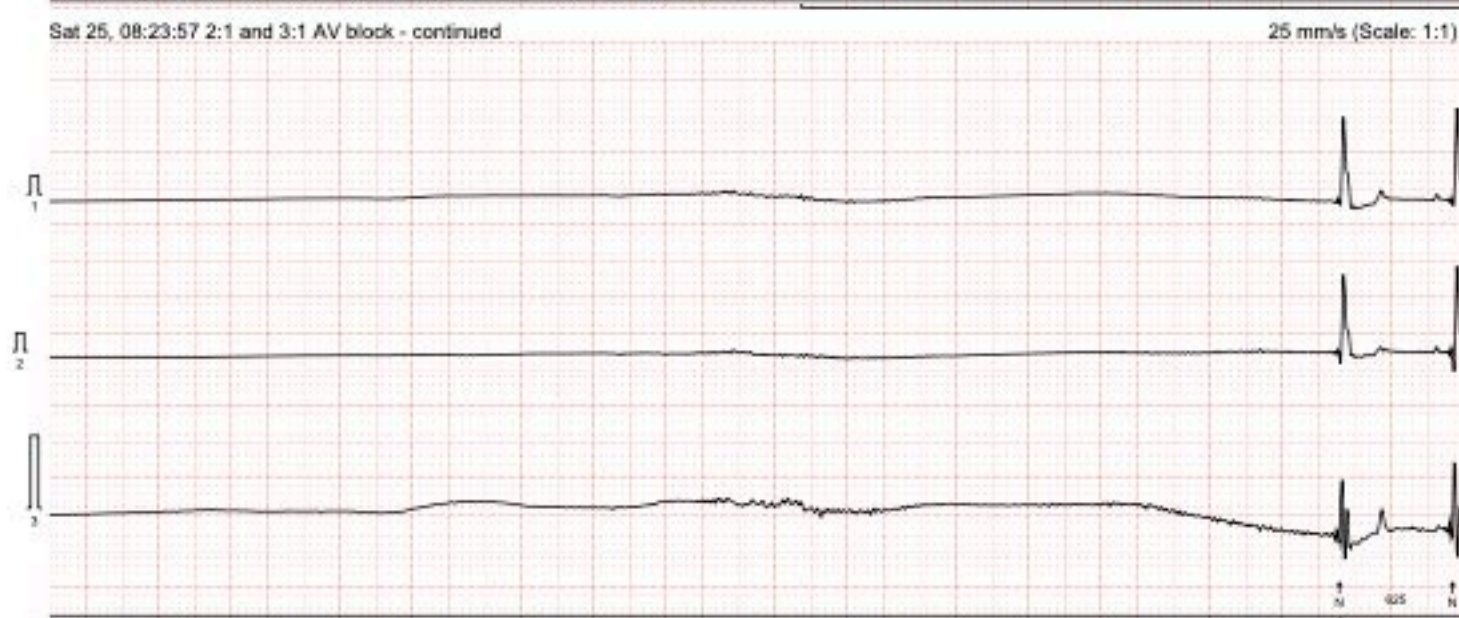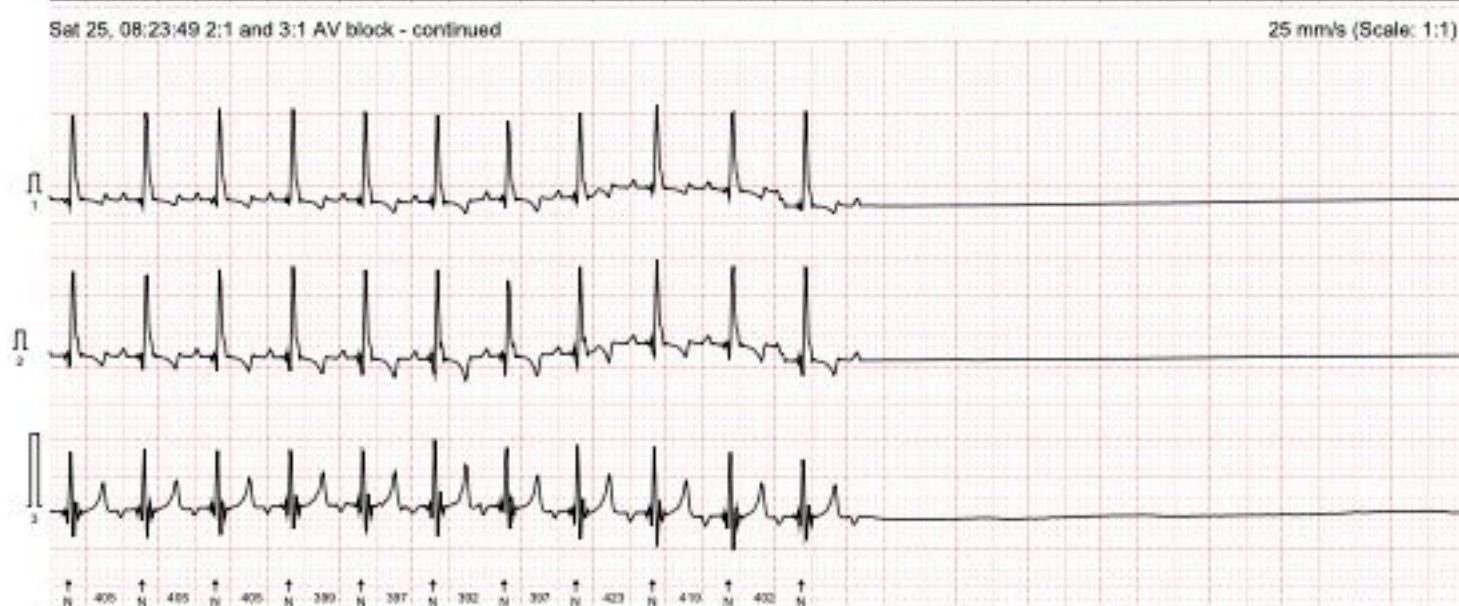
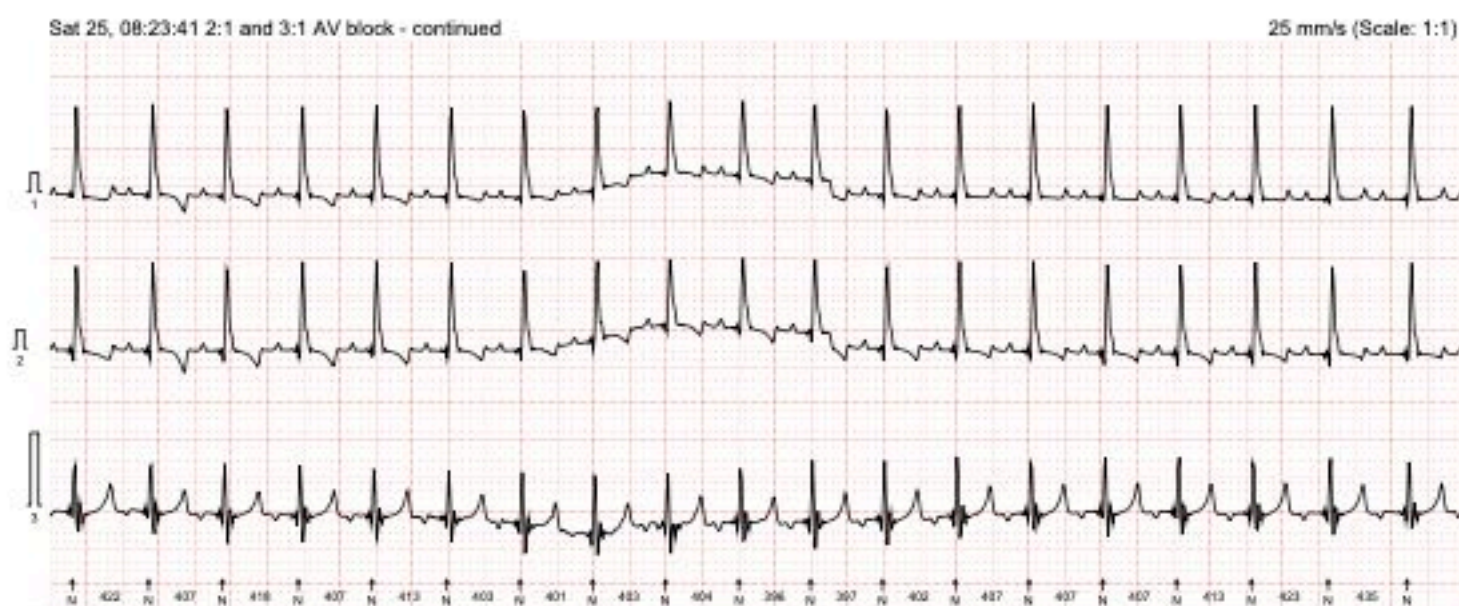# 11yo Min Schnauzer, collapsing



SVT & Sinus arrest



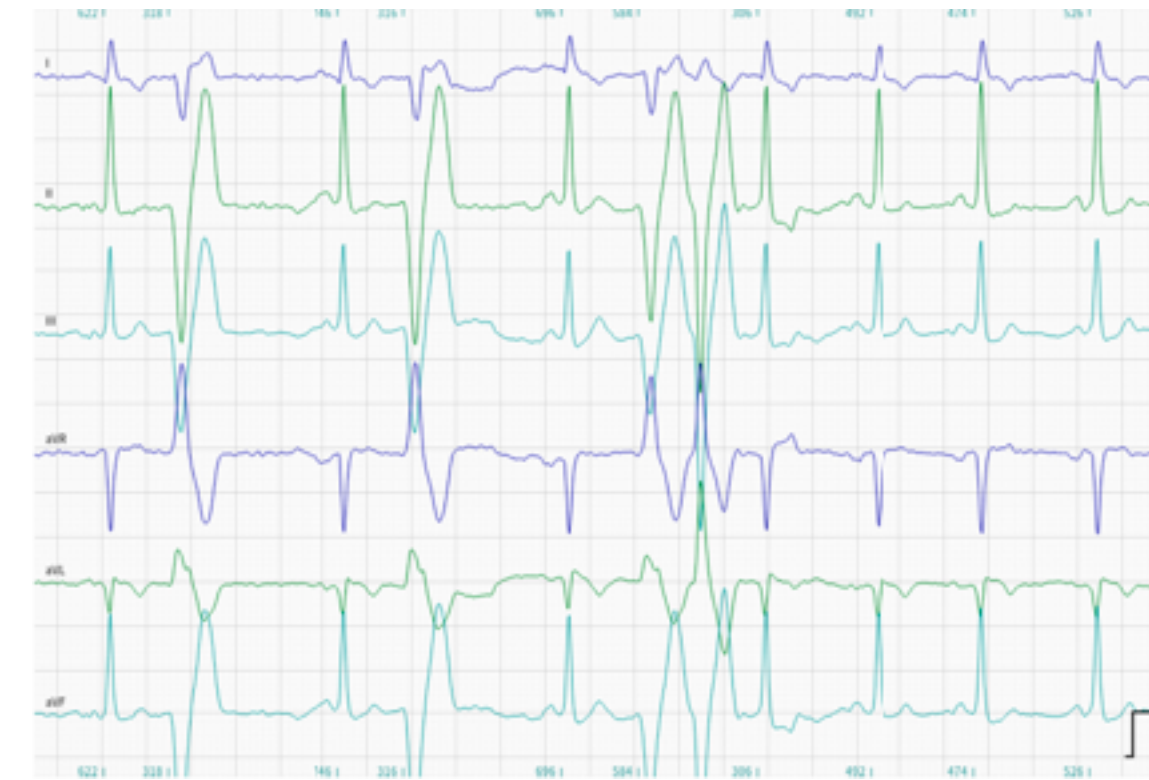
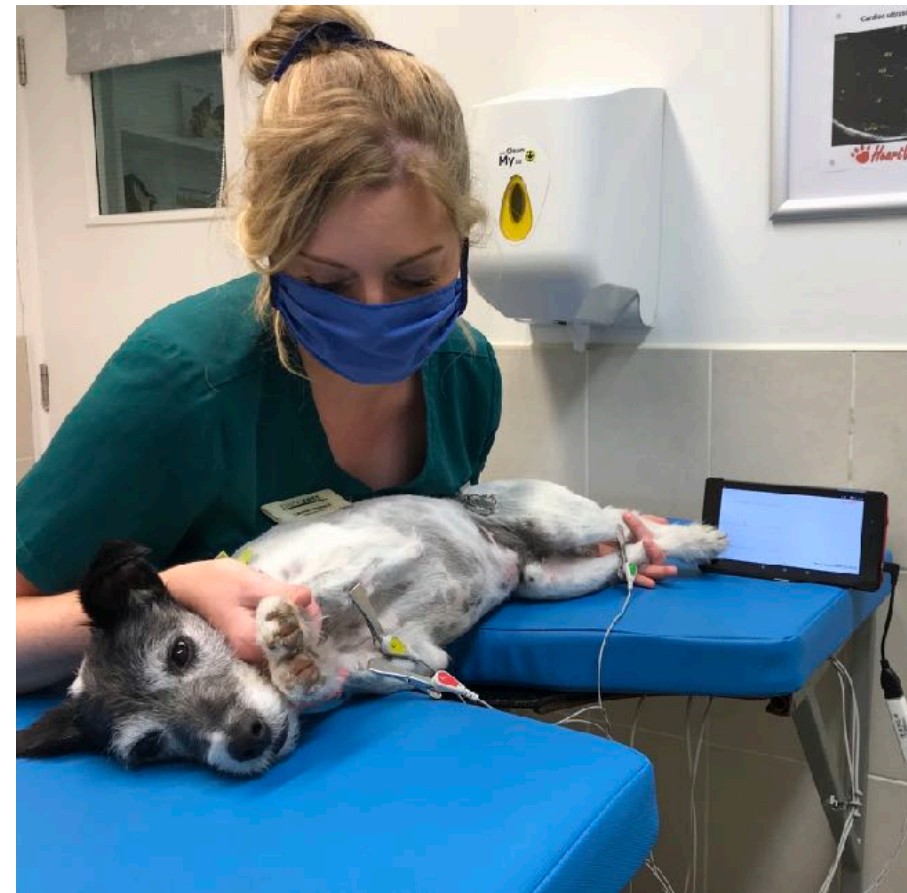

AV blocks



12s pause



# IF YOU HEAR AN ARRHYTHMIA WHAT NOW?



# IF YOU DIAGNOSE AN ARRHYTHMIA WHAT NOW?



Take a history

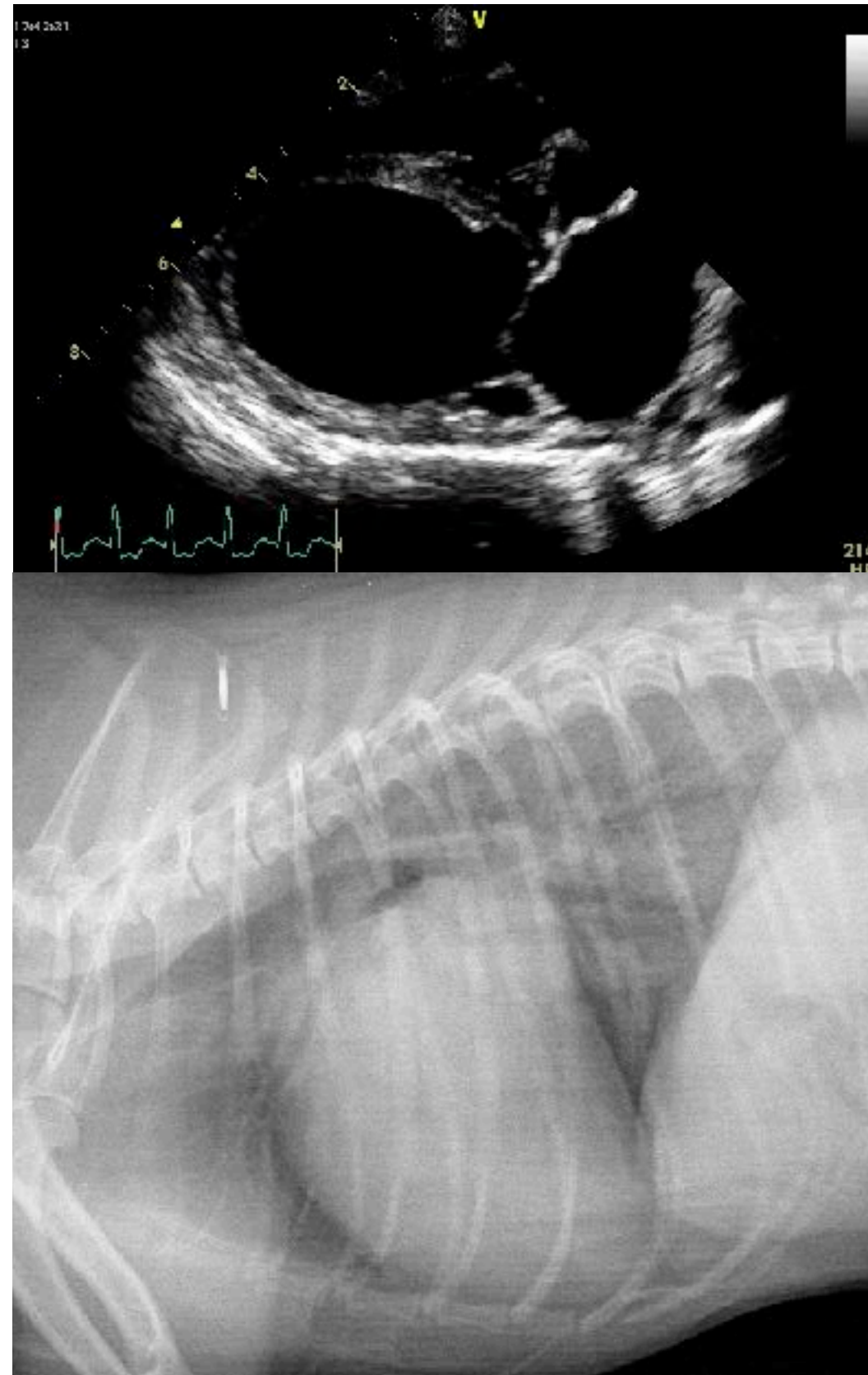
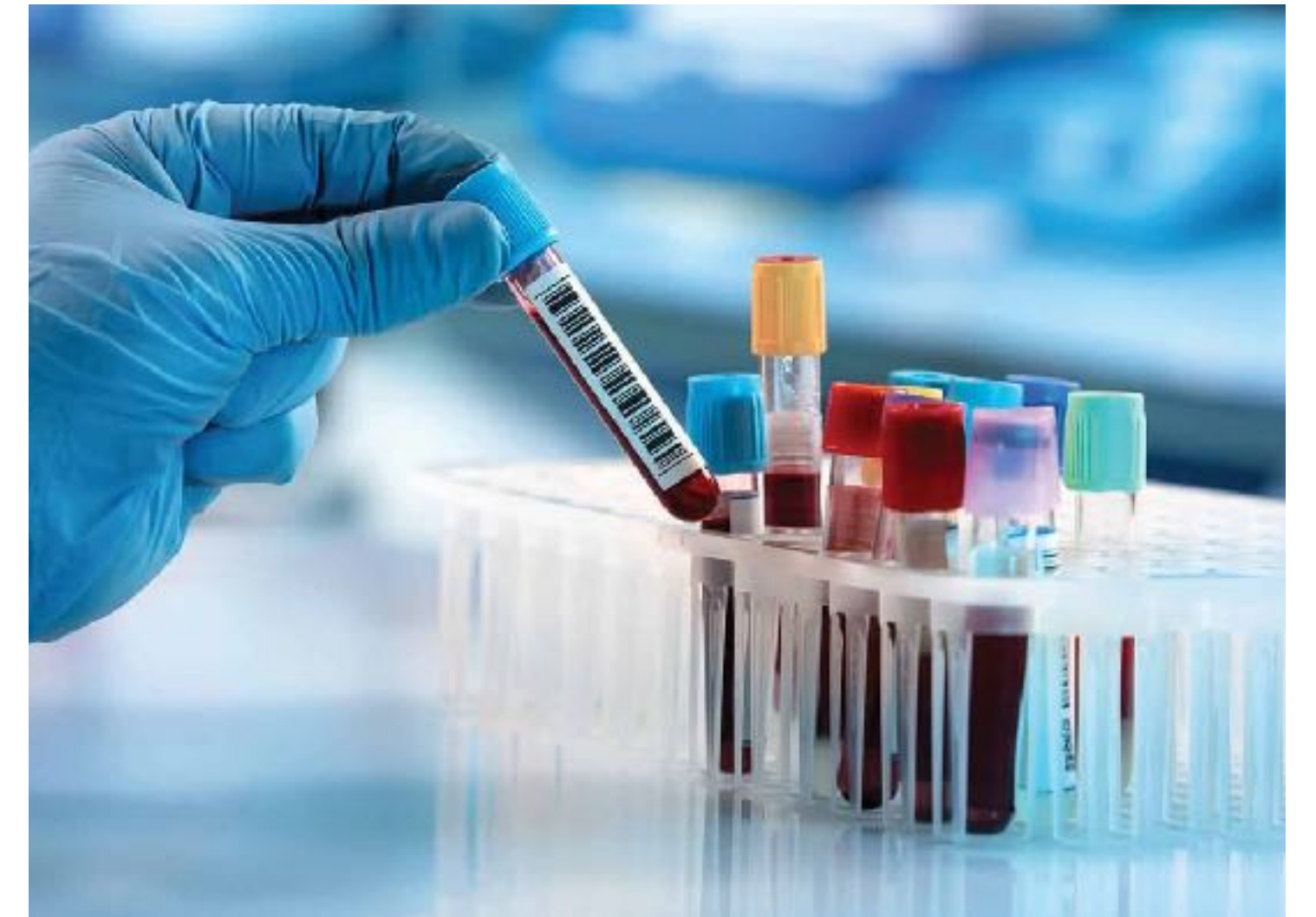

Image the heart



Run the bloods

# RULE NUMBER 5

Don't try to treat the ECG in isolation

Changes on an ECG happen for a reason

Most often, it's significant cardiac or systemic disease

So go look for them

# SOME CASE EXAMPLES

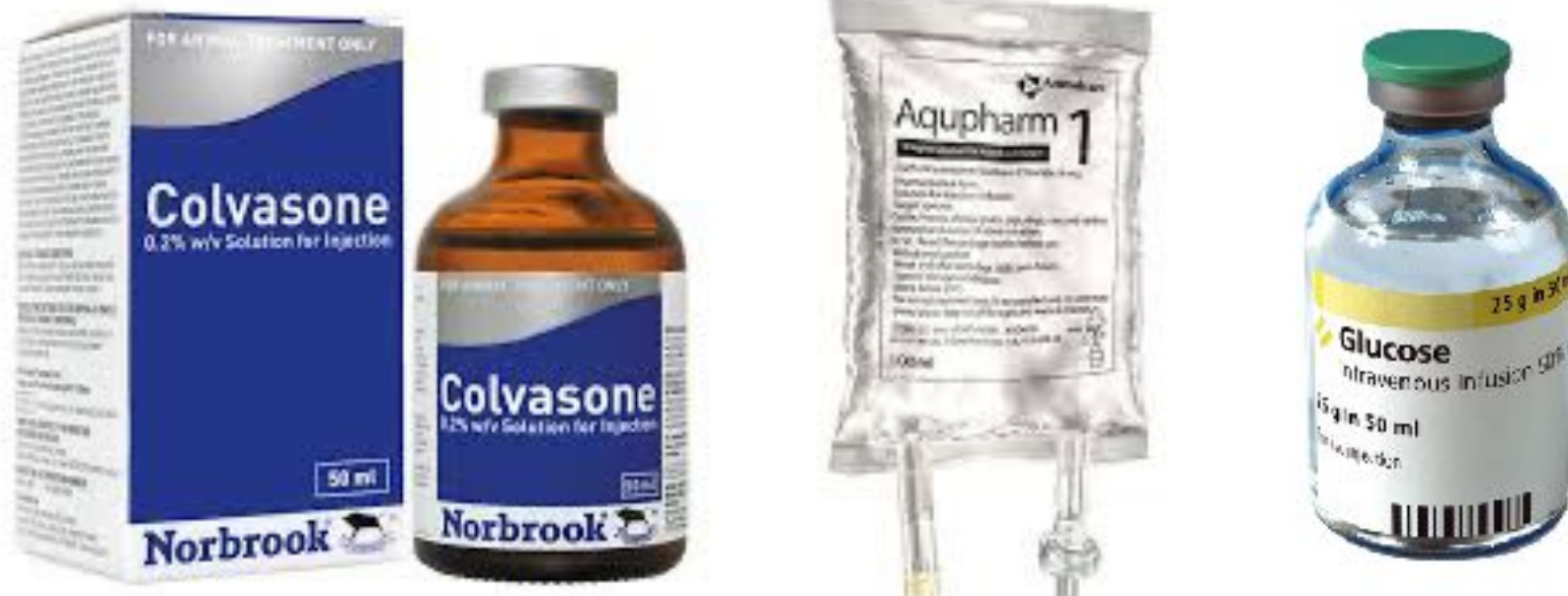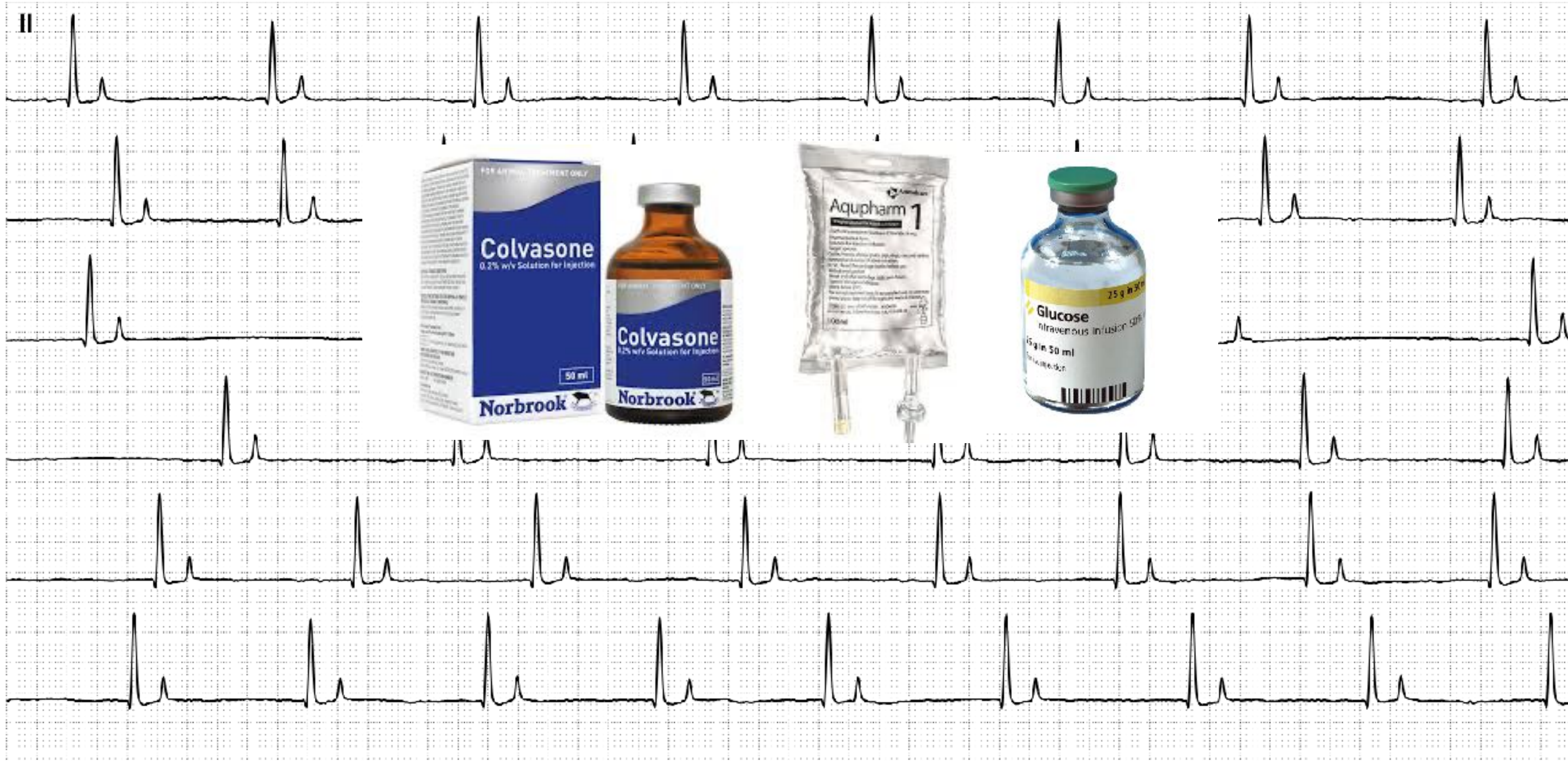
## 9yo FN Border collie

- 3 weeks prior gone off food,
- Normally very active, now slowing down and really struggling.
- Coat gone poor.
- Weight loss in last 2w.
- Bloods at RVS found mild incr in renal enz. Nothing on ultrasound of abdomen
- Several episodes of ataxia/partial collapse
- Was vomiting but this has stopped.
- Some D+



Old Hemp (ISDS 9)

# 9yo FN Border collie

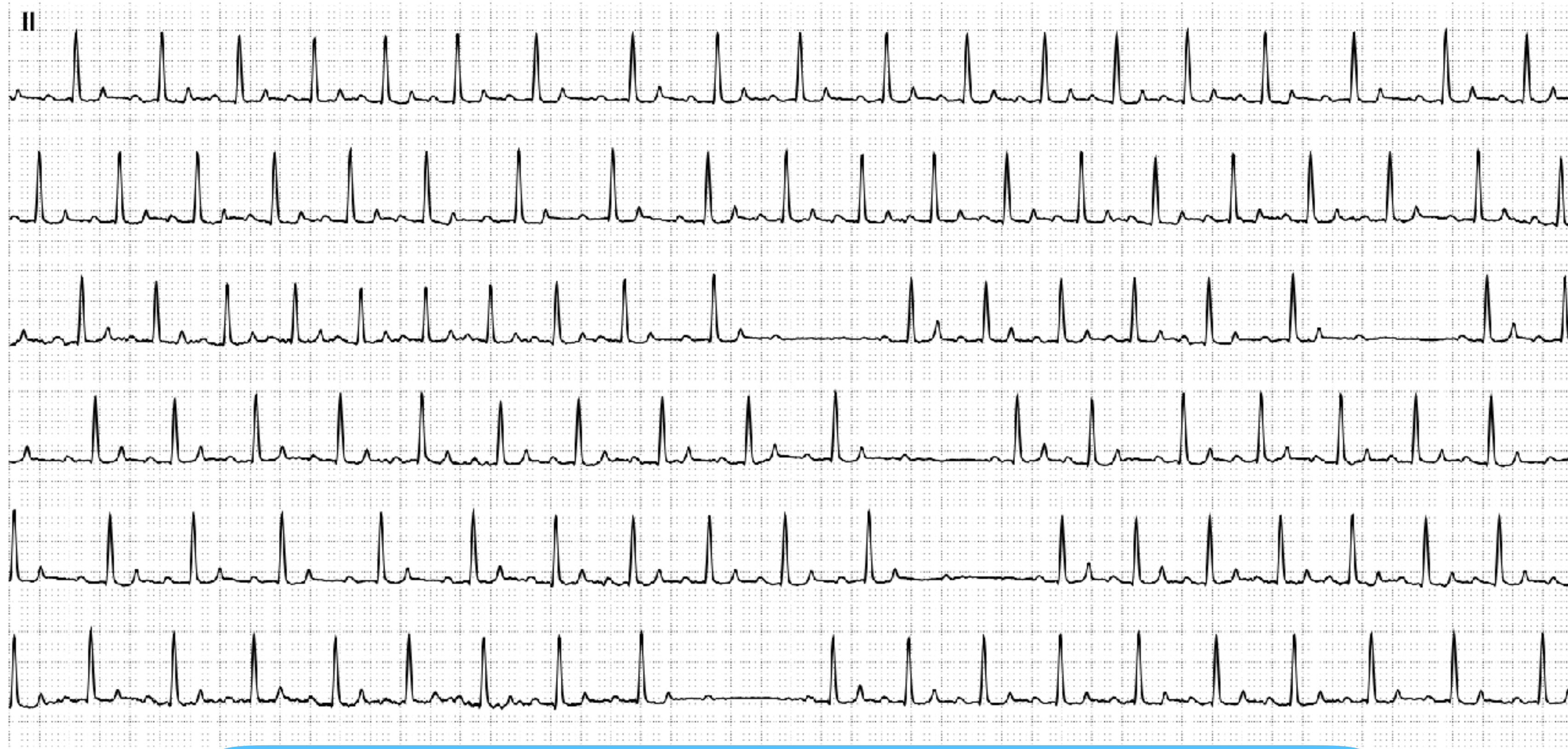

ALB	32	25-44	g/L
ALP	24	20-150	U/L
ALT	58	10-118	U/L
AMY	894	200-1200	U/L
TBIL	5	2-10	umol/L
BUN	32.0 *	2.5-8.9	mmol/L
CA	2.73	2.15-2.95	mmol/L
PHOS	2.52 *	0.94-2.13	mmol/L
CRE	184 *	27-124	umol/L
GLU	4.9	3.3-6.1	mmol/L
NA+	125 *	138-160	mmol/L
K+	8.5 *	3.7-5.8	mmol/L
TP	60	54-82	g/L
GLOB	28	23-52	g/L
QC	OK		
HEM	0	LIP 0	ICT 0

**K+ 8.5**



## 9yo FN Border collie

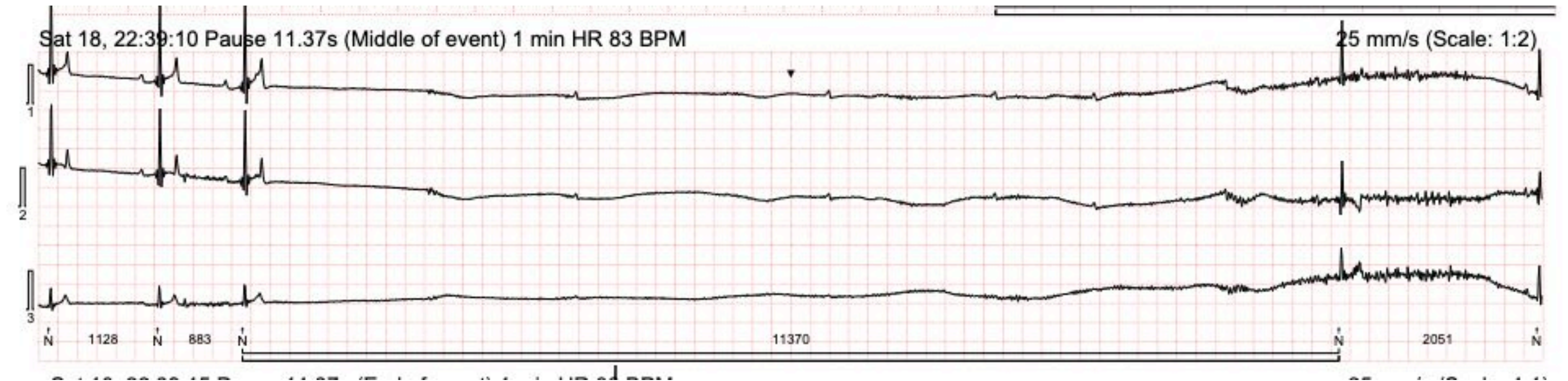

Sinus rhythm with first and occasional second-degree AV block  
Addison's confirmed on ACTH stimulation  
Treatment for HypoA successful

# 9 YEAR-OLD LABRADOR

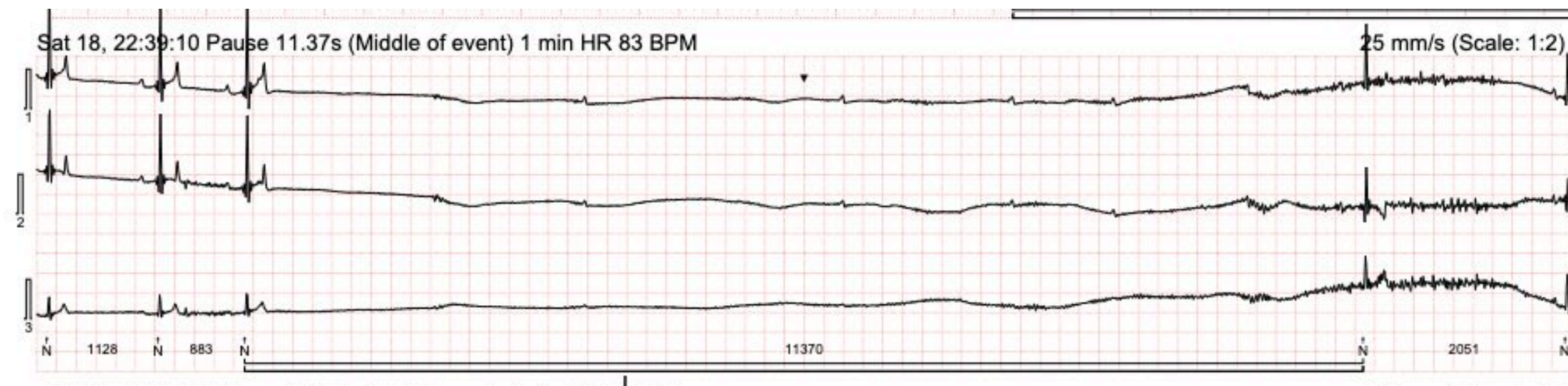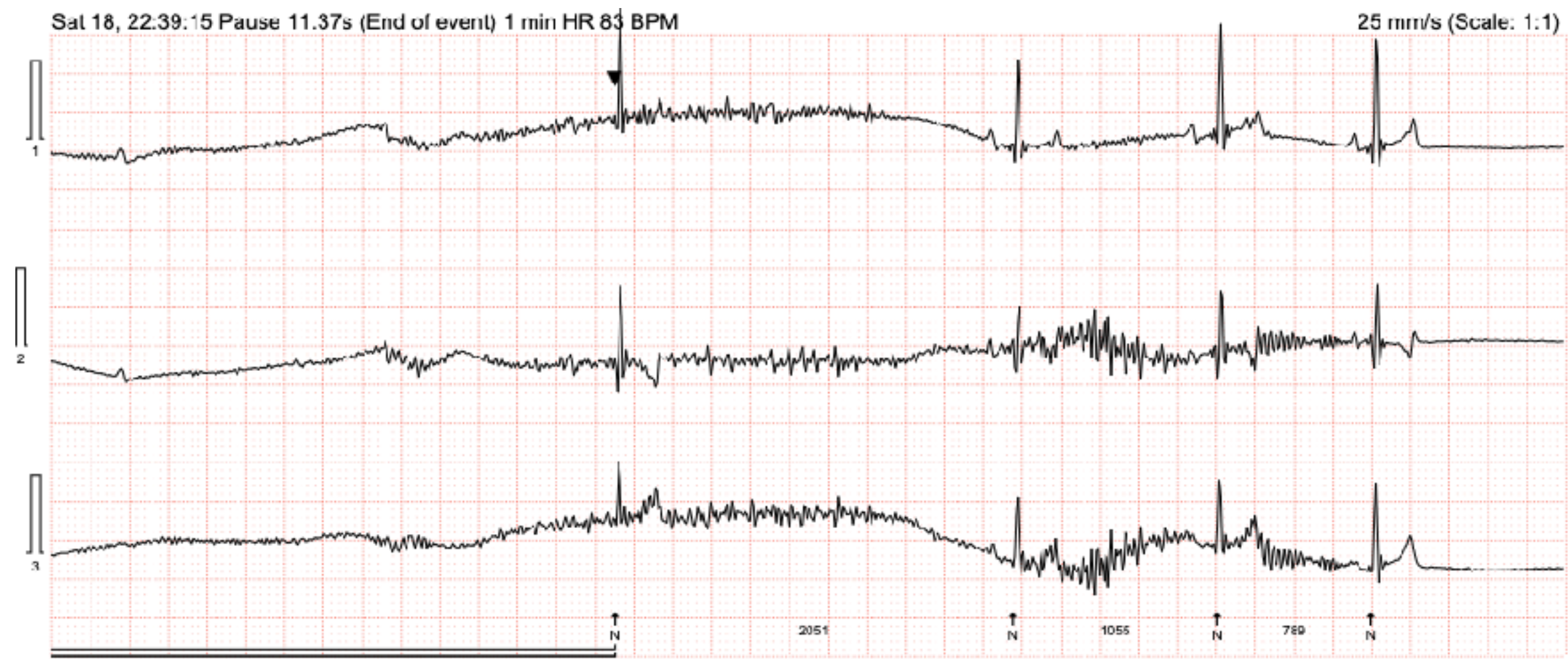

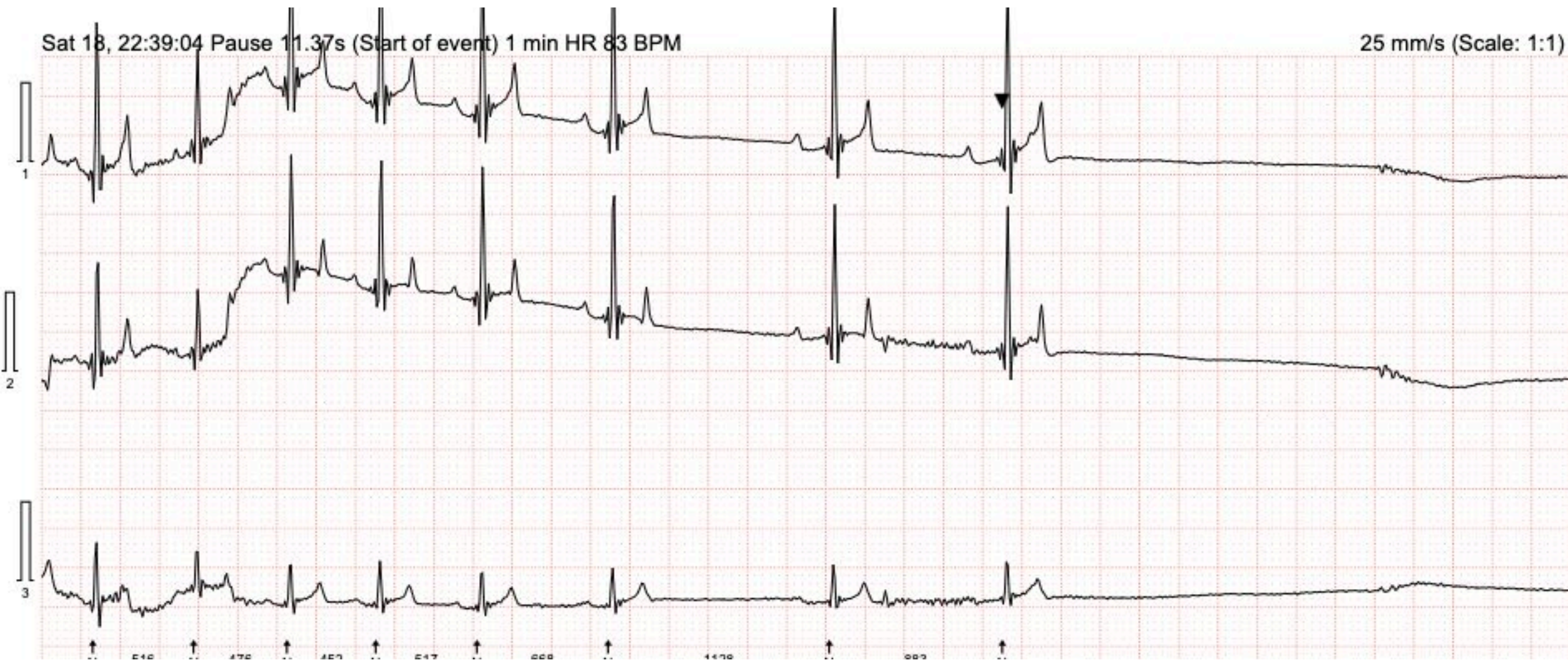
# VASO-VAGAL SYNCOPE






# VASO-VAGAL SYNCOPE



# VASO-VAGAL SYNCOPE




Echo - UNR

Bloods - UNR

BP - 130mmHg

Neuro - normal



Time



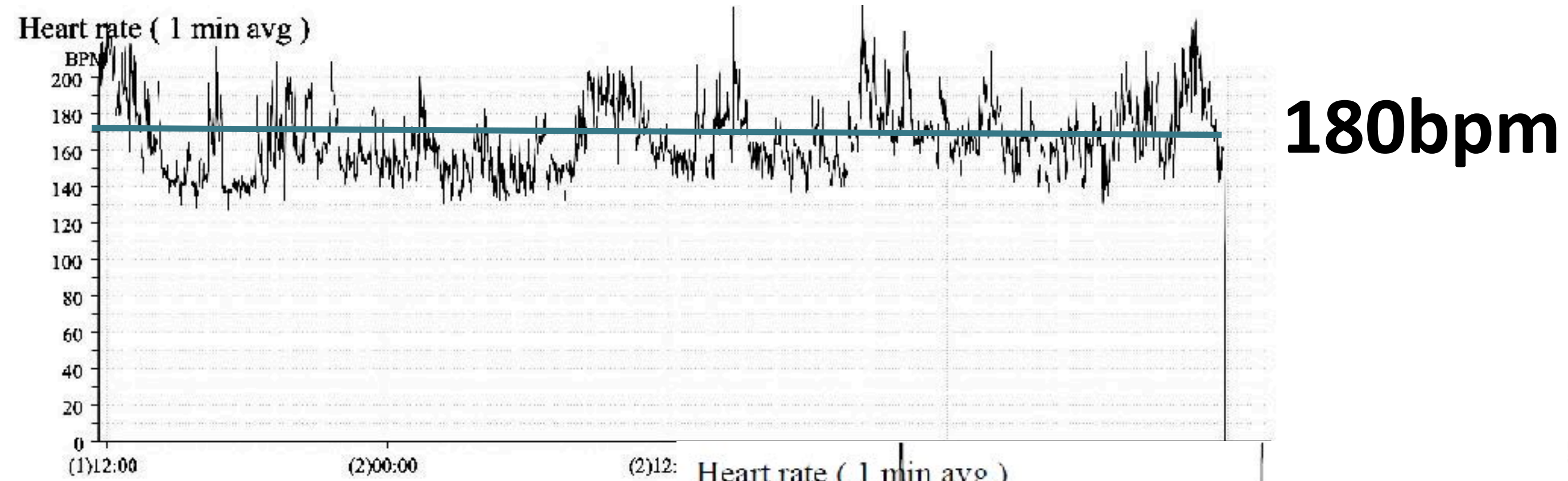
Pimobendan



Theophylline

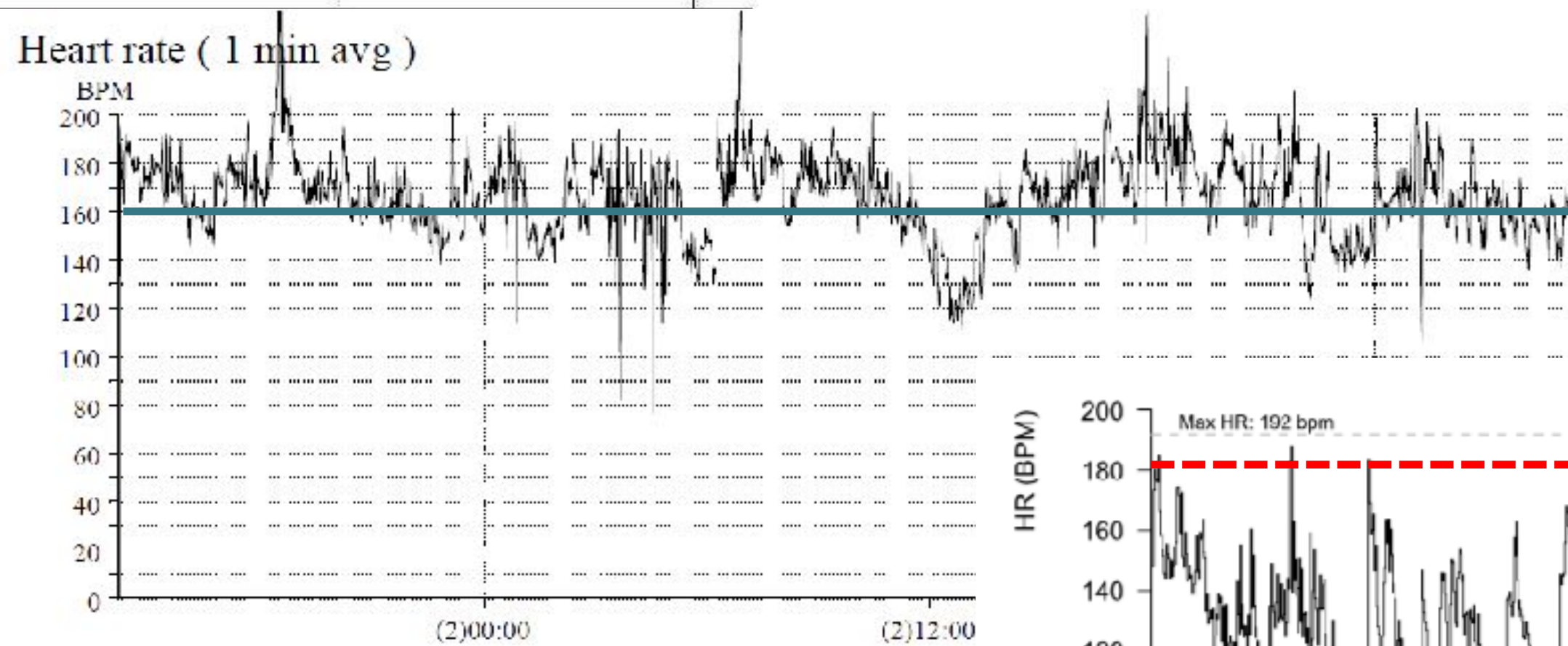


# ATRIAL FIBRILLATION: MONITORING DURING TREATMENT

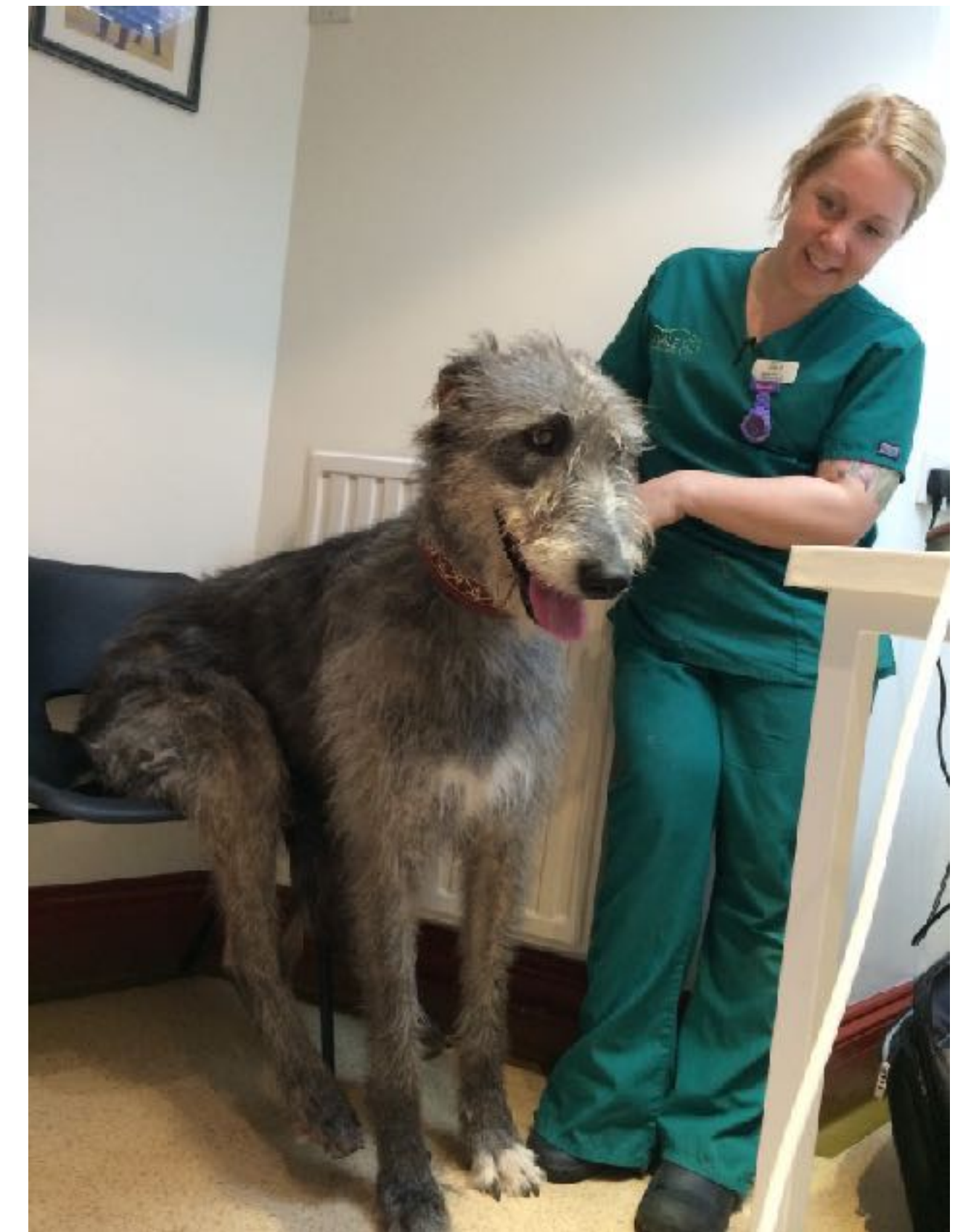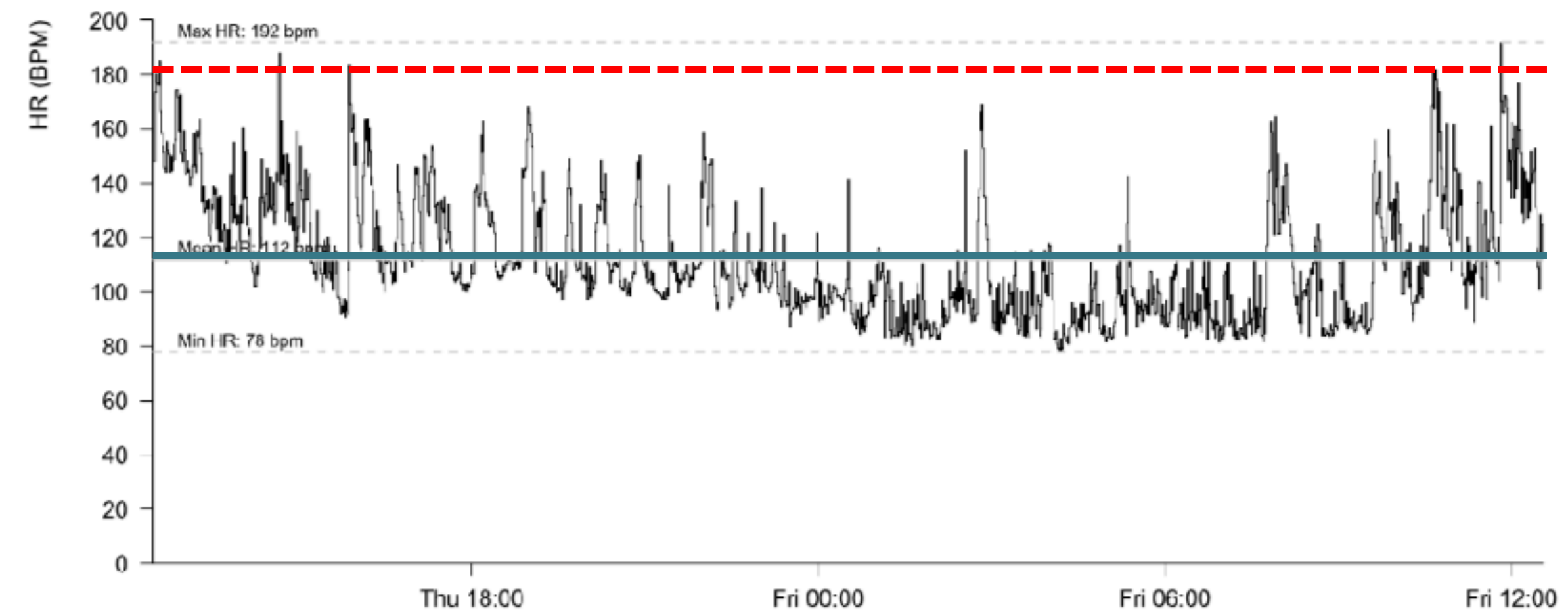


**160bpm**

**Digoxin**

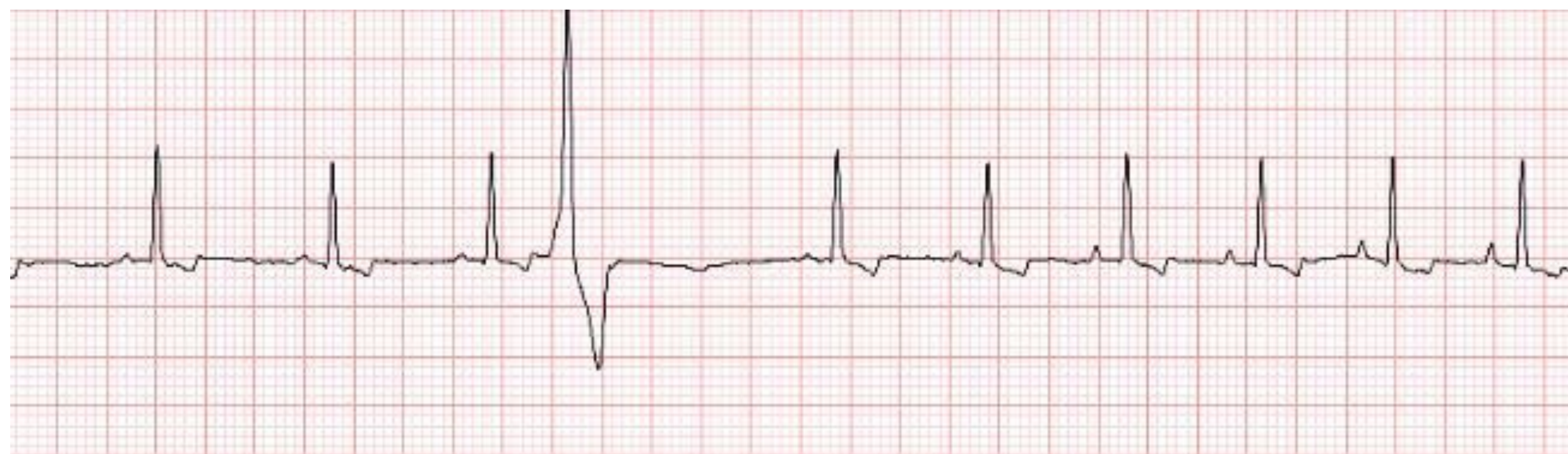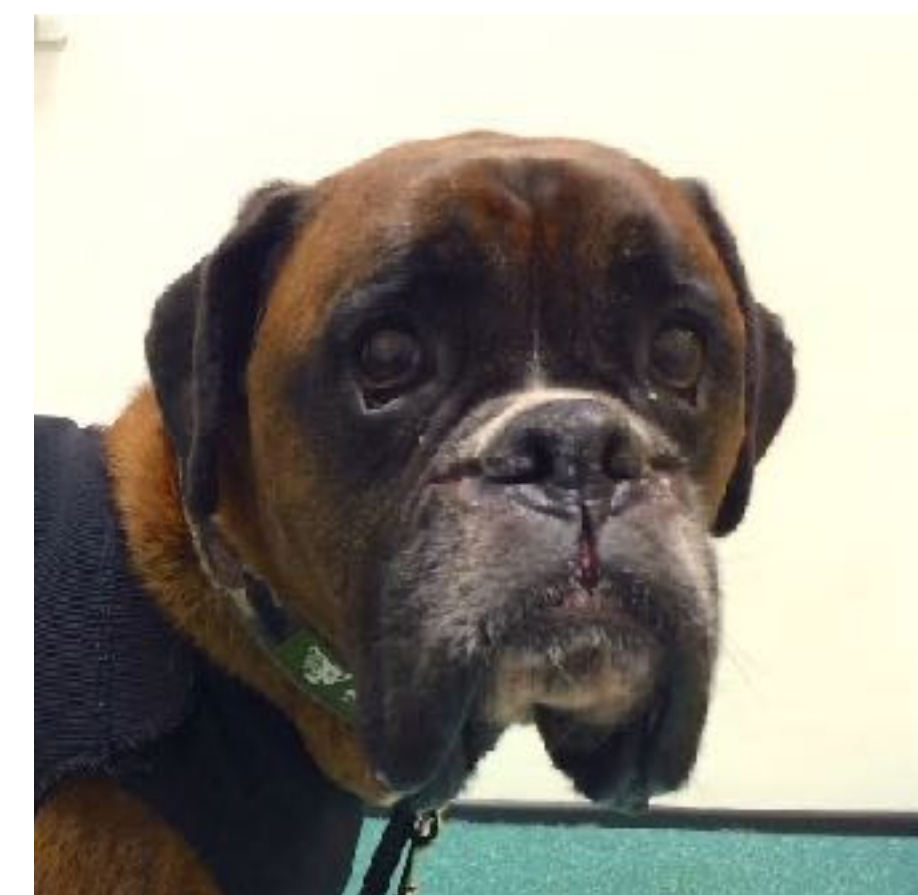


**Digoxin & Diltiazem 112bpm**

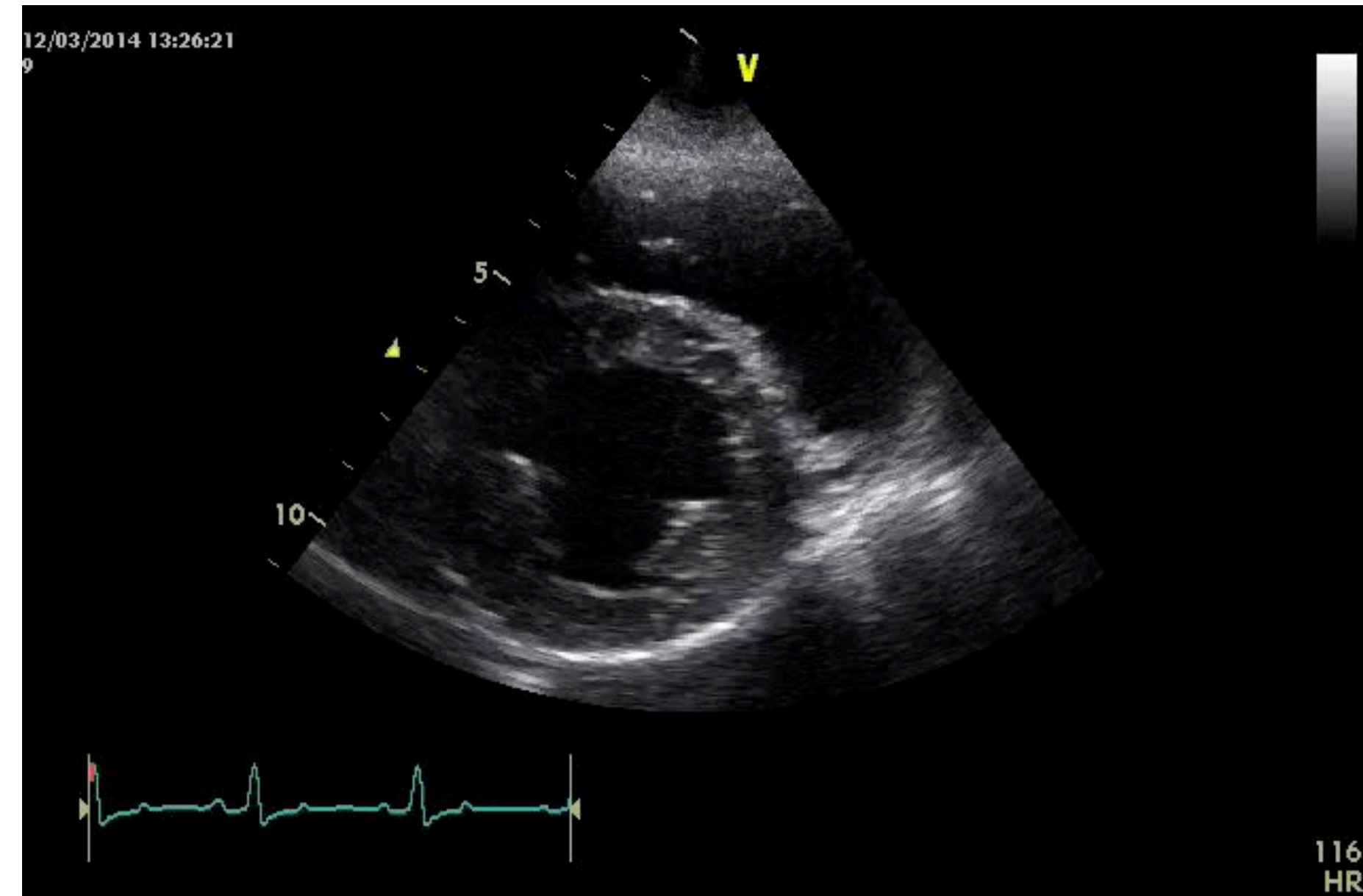
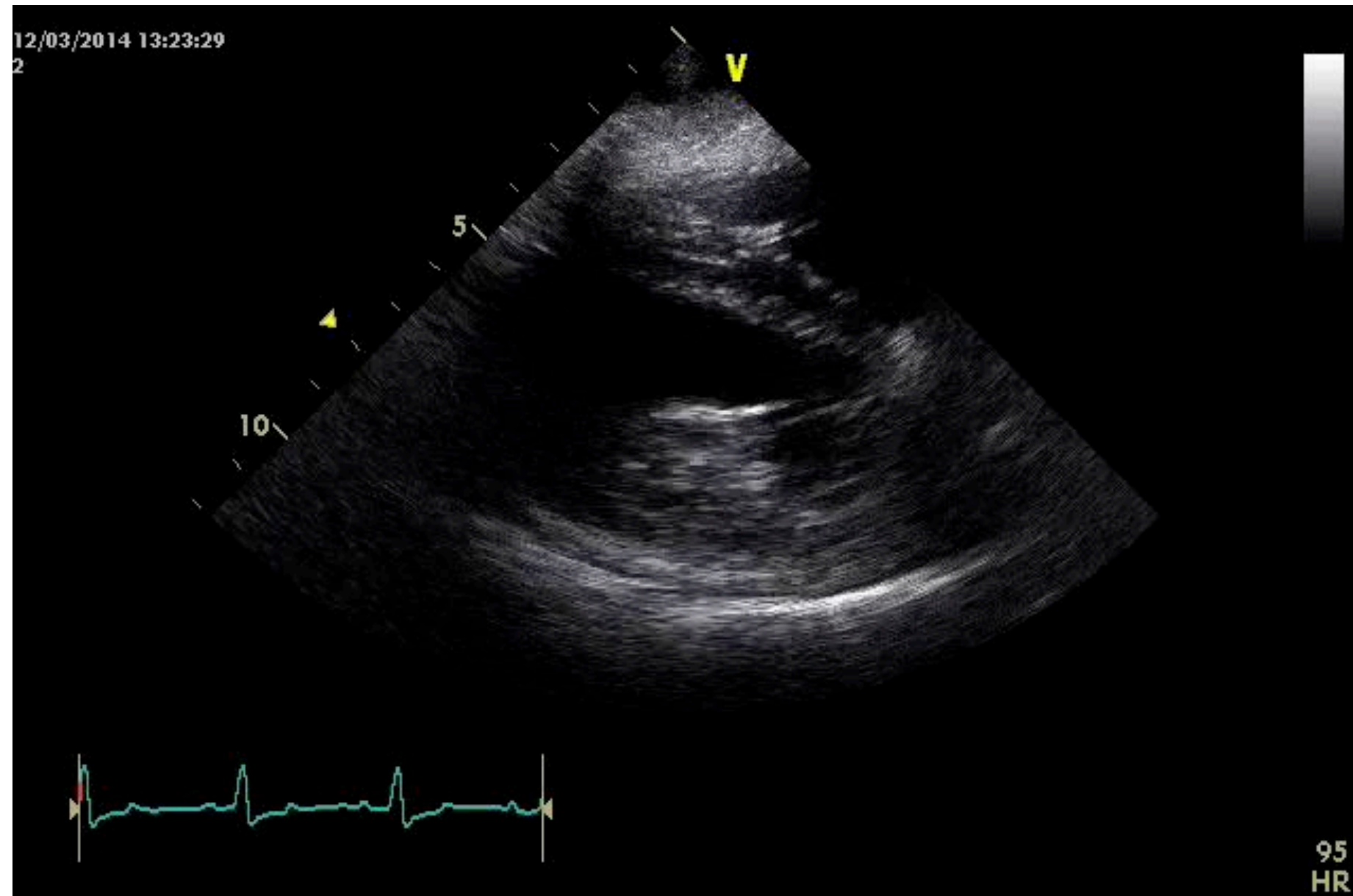
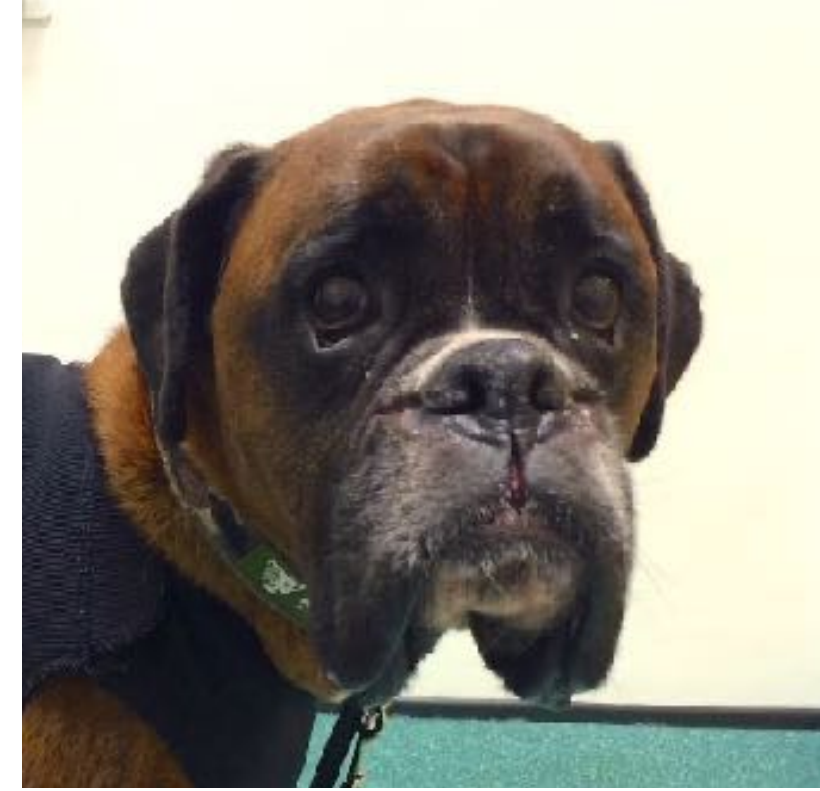

# JACK

- 6yo MN Boxer “Jack”
- No clinical signs, vaccine consult
- G2/6 holosystolic ejection murmur, otherwise NAD
- Occasional arrhythmia
- HR 120bpm
- Family history of SCD

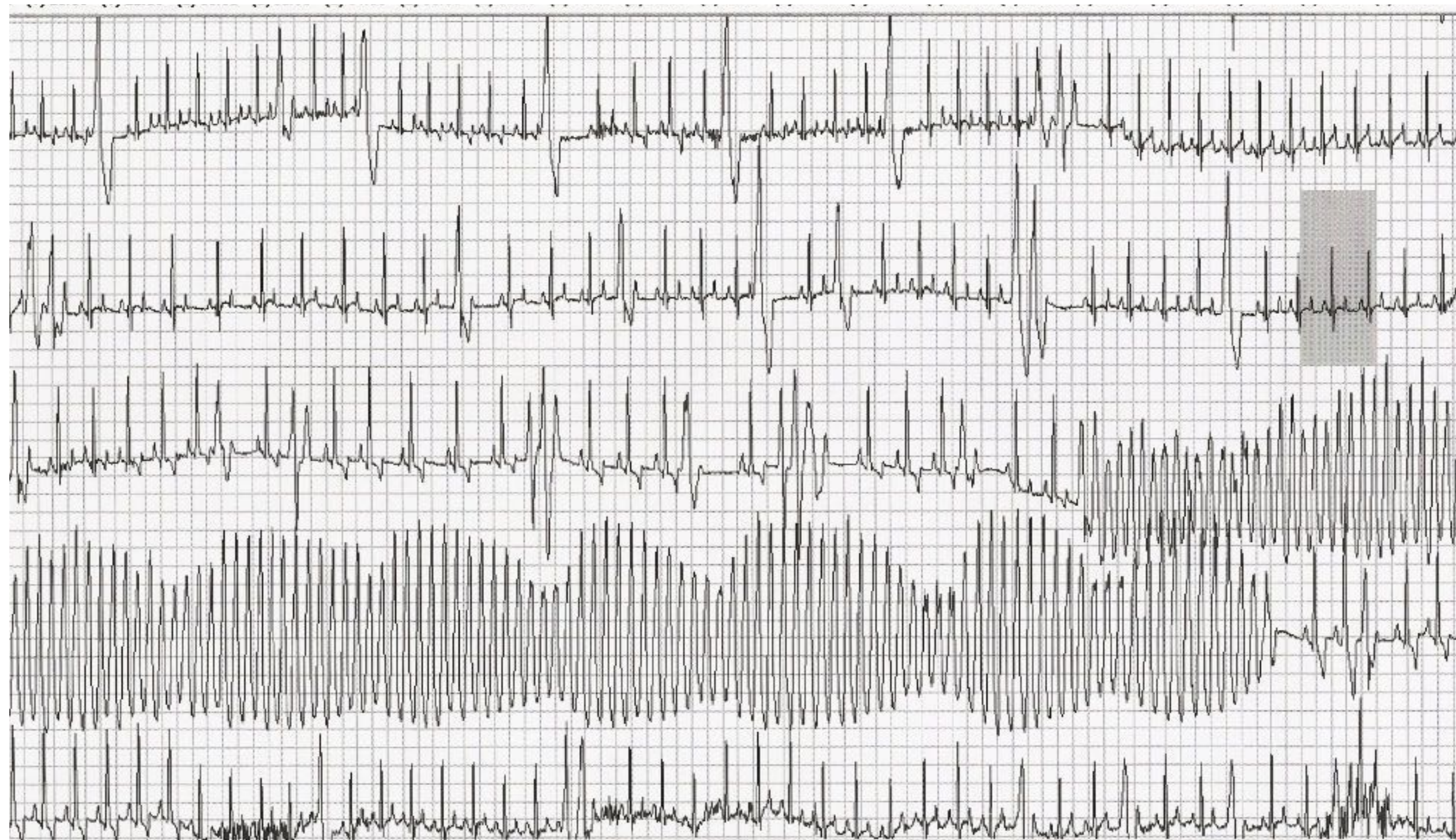


# JACK



Structurally normal echo (physiologic murmur)

# JACK



# HOLTER TO GUIDE TREATMENT DECISIONS



Day 1



Ventricular Arrhythmias

<b>VT</b>	8,537, 19.2% of total beats (191 per 1000)
Longest	55 beats on Wed 25, 20:24:24
Max Rate	283 bpm on Wed 25, 20:32:21
<b>V-Run/AIVR</b>	2,585, 2.9% of total beats (29 per 1000)
Longest	6 beats on Tue 24, 18:43:07
Max Rate	269 bpm on Wed 25, 20:59:53
<b>Couplet</b>	3,861, 2.2% of total beats (21 per 1000)
<b>Triplet</b>	2,973, 2.5% of total beats (24 per 1000)
<b>Single VE Events</b>	18,249, 5.1% of total beats (51 per 1000)

Day 21



Ventricular Arrhythmias

<b>VT</b>	0, 0.0% of total beats (0 per 1000)
Longest	
Max Rate	
<b>V-Run/AIVR</b>	4, 0.0% of total beats (0 per 1000)
Longest	7 beats on Tue 17, 23:06:00
Max Rate	311 bpm on Tue 17, 15:53:42
<b>Couplet</b>	5, 0.0% of total beats (0 per 1000)
<b>Triplet</b>	1, 0.0% of total beats (0 per 1000)
<b>Single VE Events</b>	1,309, 0.6% of total beats (6 per 1000)

Day 42



Ventricular Arrhythmias

<b>VT</b>	0, 0.0% of total beats (0 per 1000)
Longest	
Max Rate	
<b>V-Run/AIVR</b>	0, 0.0% of total beats (0 per 1000)
Longest	
Max Rate	
<b>Couplet</b>	1, 0.0% of total beats (0 per 1000)
<b>Triplet</b>	0, 0.0% of total beats (0 per 1000)
<b>Single VE Events</b>	49, 0.0% of total beats (0 per 1000)

Sotalol 2mg/kg BID

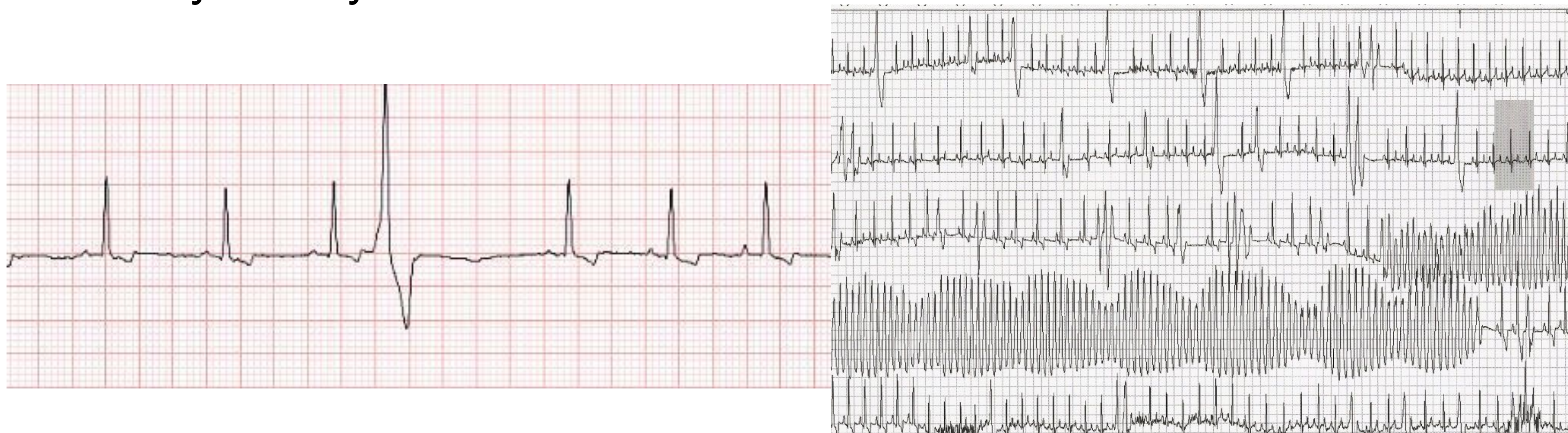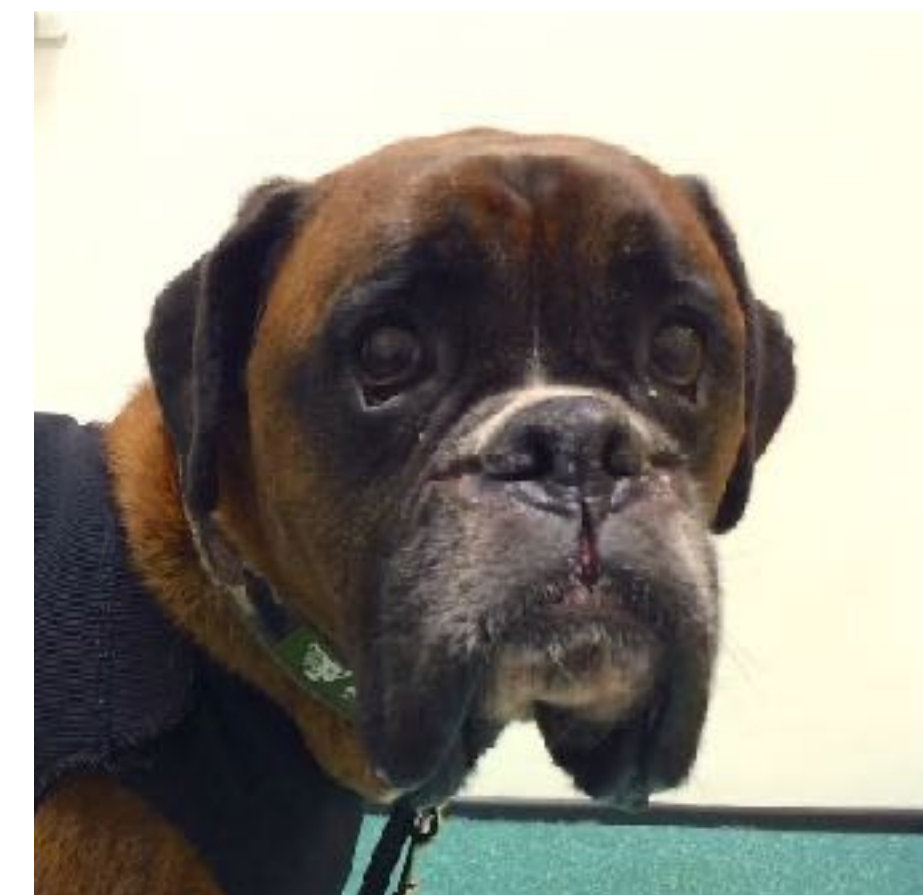
Sotalol 2mg/kg BID

+

Mexiletine 5mg/kg TID

# JACK

- 6yo MN Boxer “Jack”
- No clinical signs, vaccine consult
- G2/6 holosystolic ejection murmur, otherwise NAD
- Occasional arrhythmia
- HR 120bpm
- Family history of SCD



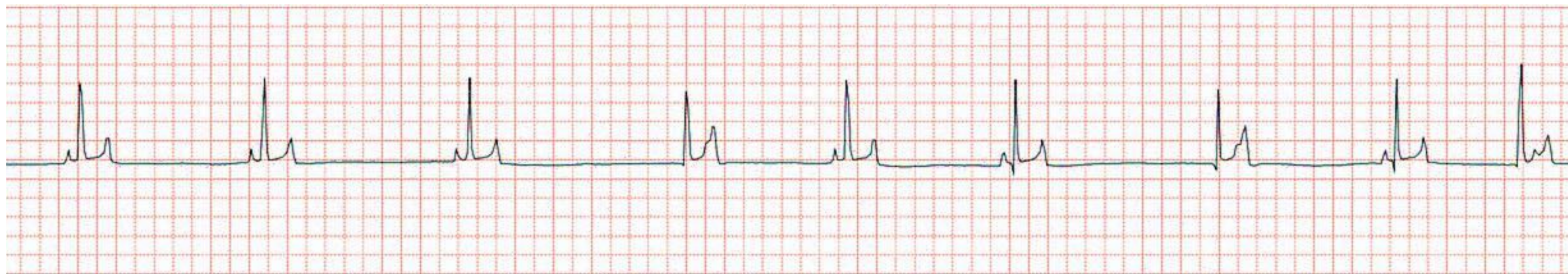# SCOOBY



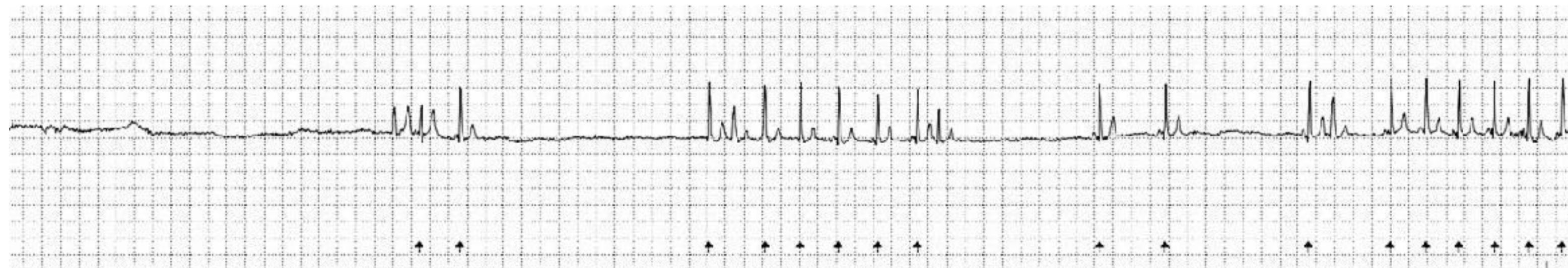
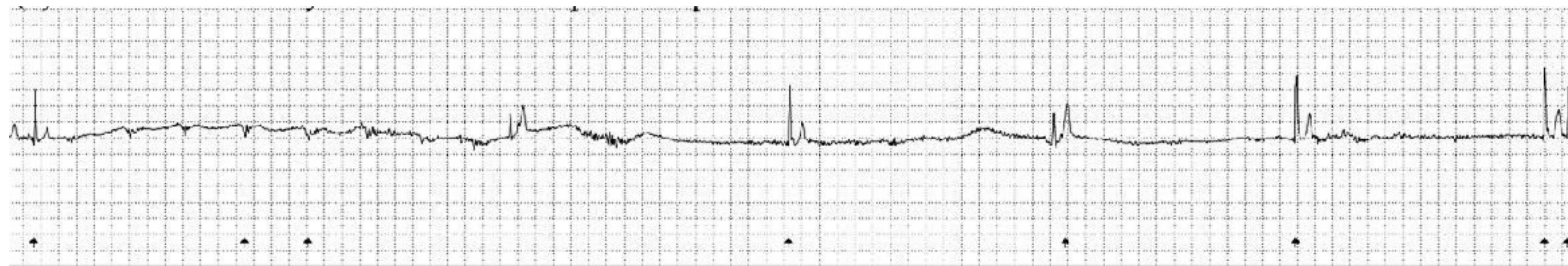
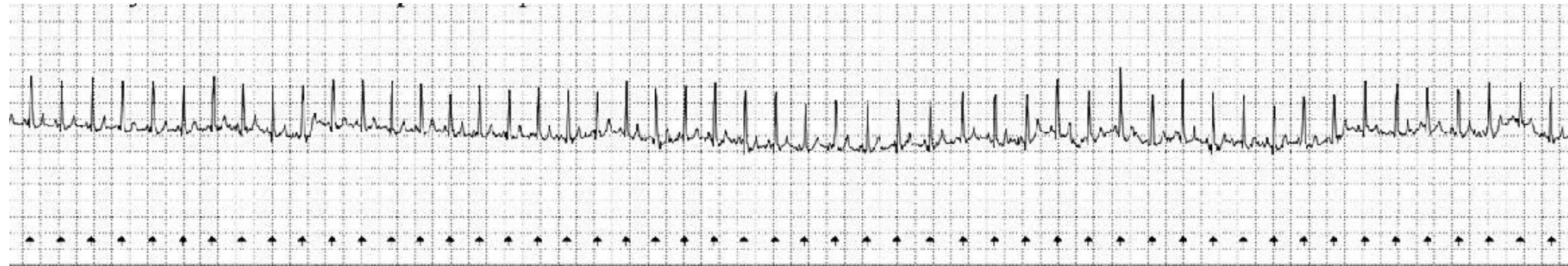
12yo MN WHWT

Multiple episodes of syncope/ presyncope

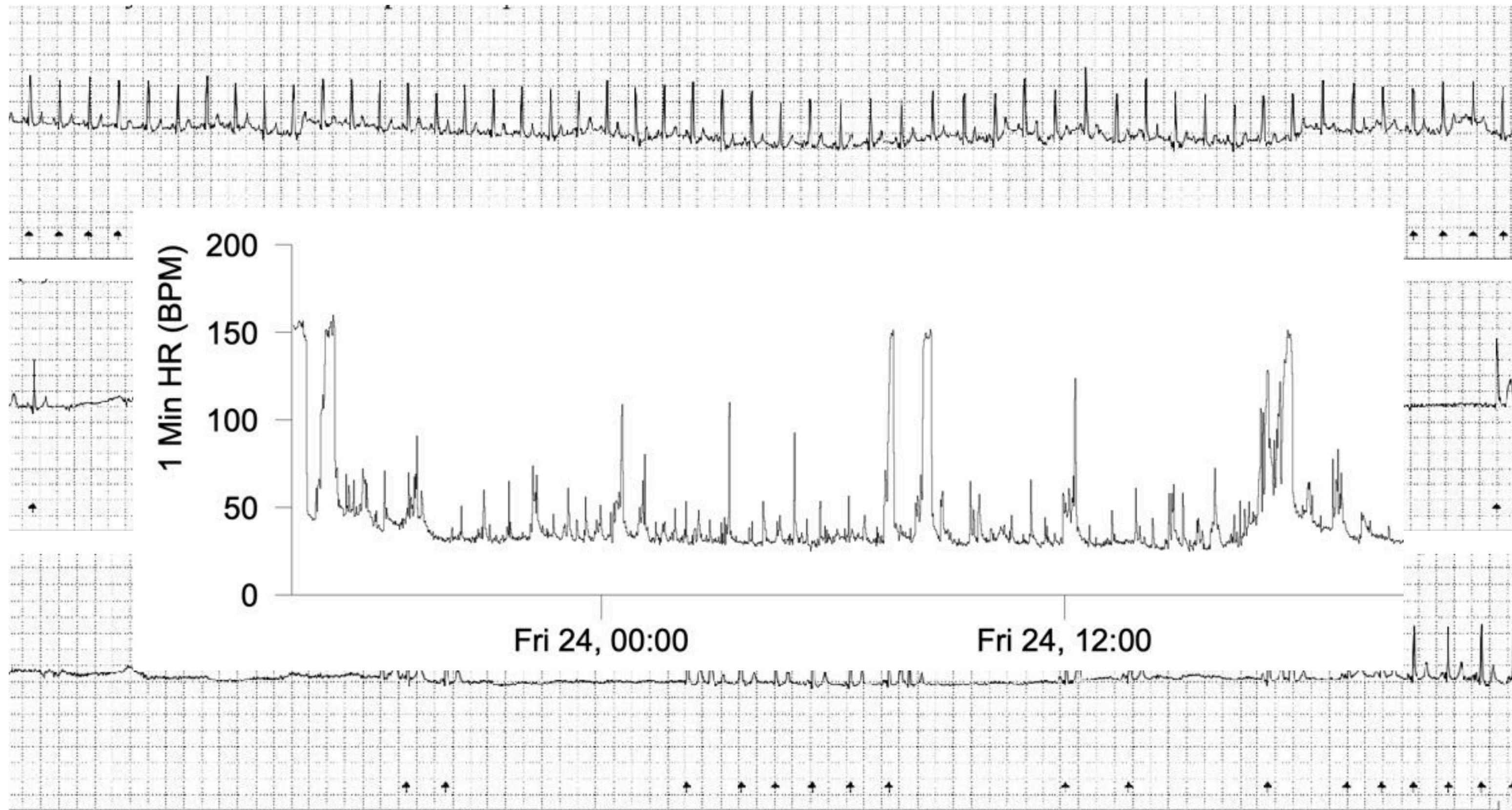ECG – sinus rhythm, intermittent junctional rhythm and sinus pauses, HR 48bpm



# SCOOBY

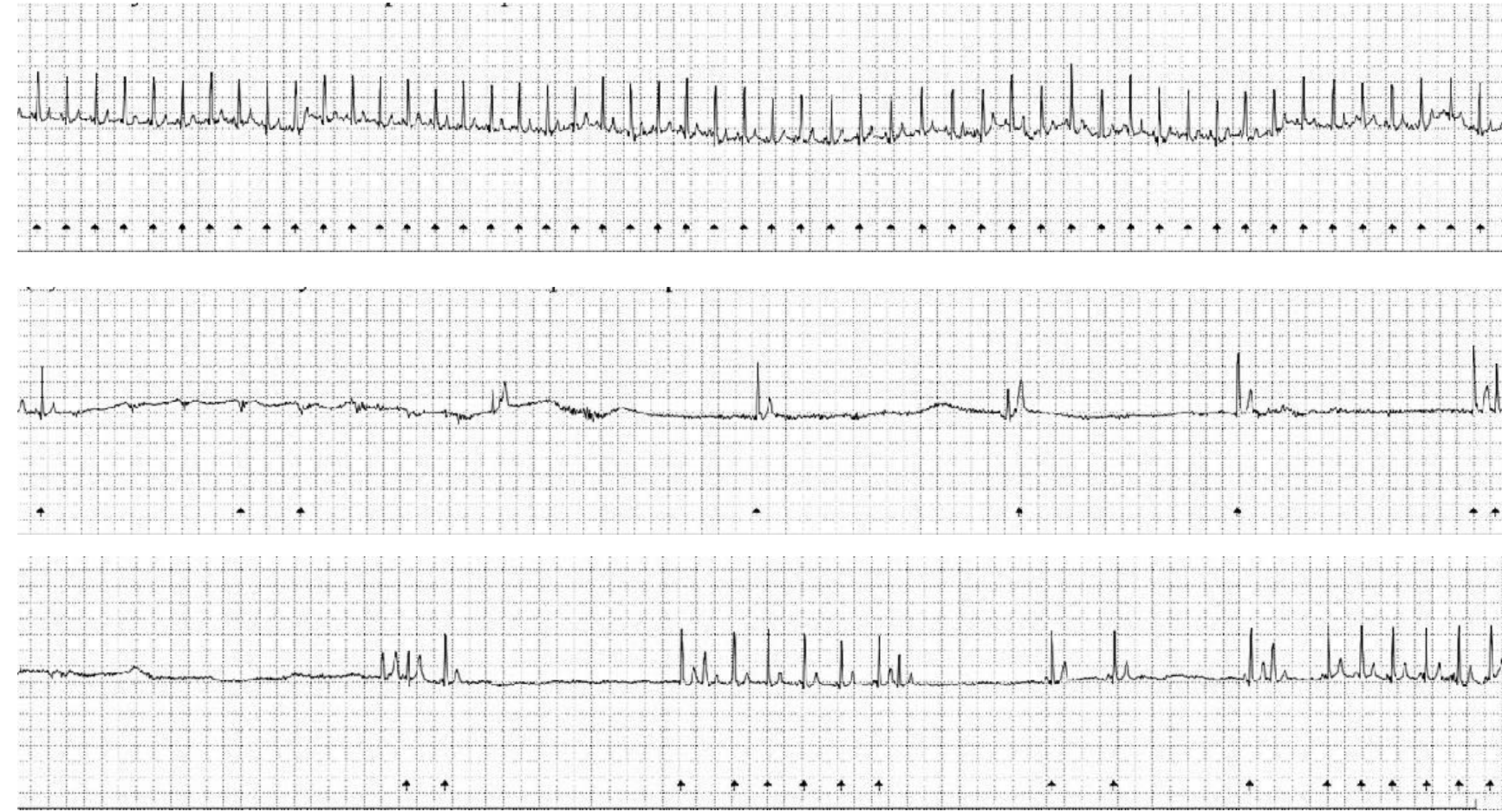

# SCOOBY

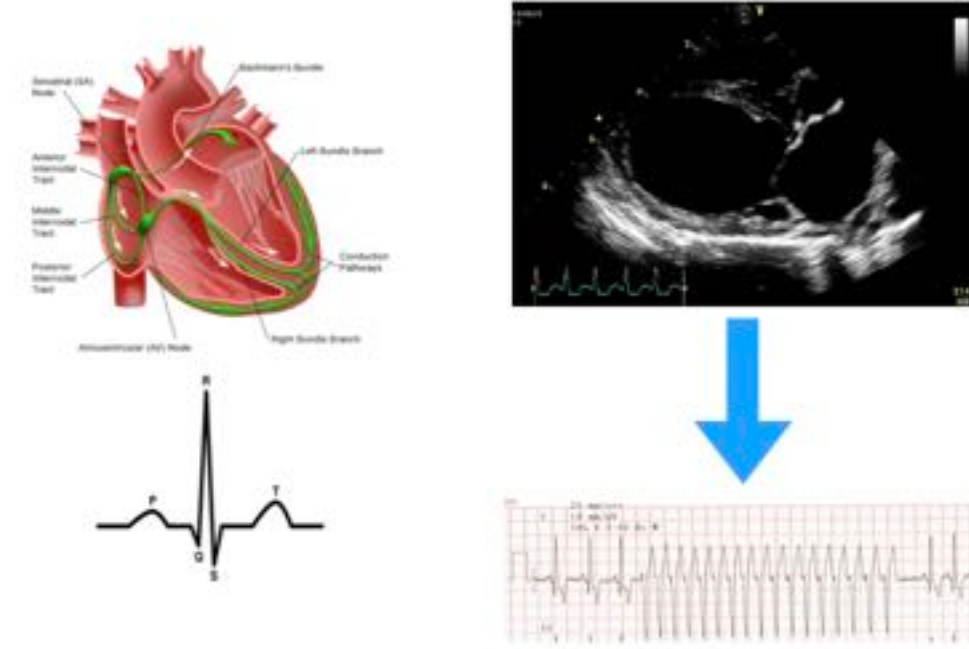


Sick sinus syndrome (bradycardia) – typically elderly patients

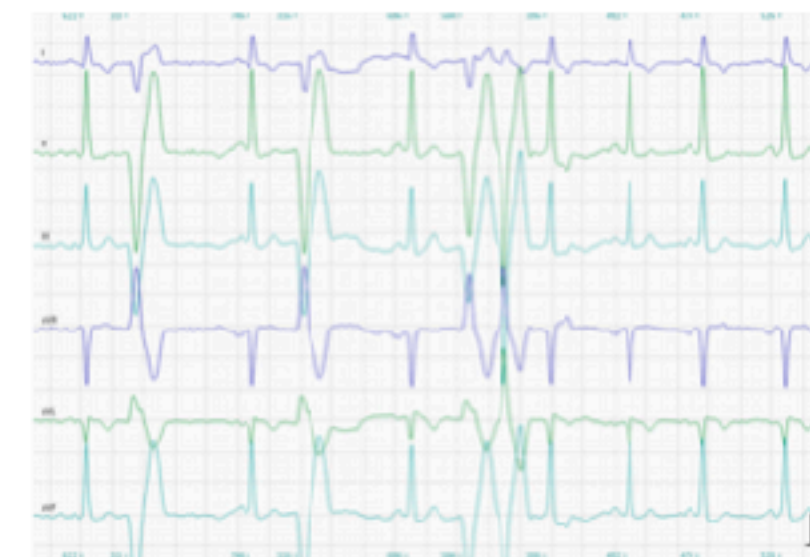
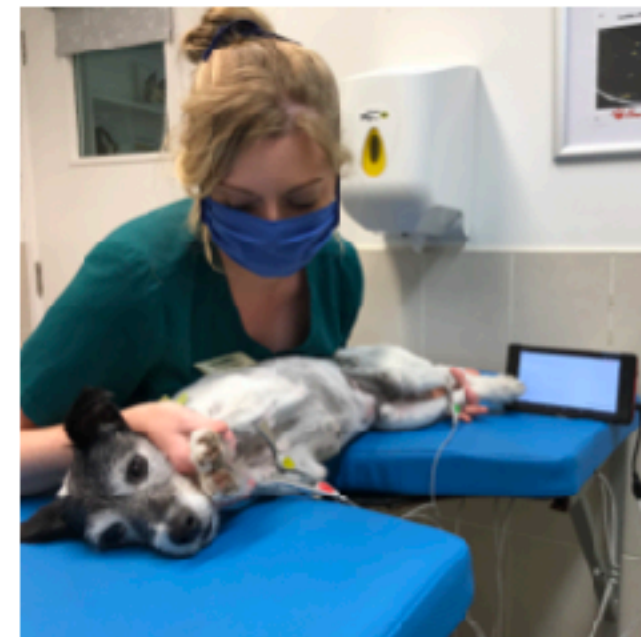# SCOOBY



# YES, ECGs ARE HARD



**BUT REALLY ALL YOU NEED TO KNOW IS  
HOW AND WHEN TO RECORD THEM**



# RECAP THE RULES

**Rule 1: Movement to Minimum:** patient relaxed, electrodes comfortable, patient still

**Rule 2: As many leads as possible:** record more than one lead (3 absolute minimum)

**Rule 3: Some is good; more is better:** record plenty of trace

**Rule 4: Record an ECG if:**

- a) You hear or see something abnormal
- b) The heart rate is too fast or too slow
- c) The patient is collapsing
- d) As part of a detailed cardiac investigation

**Rule 5: Don't try to treat the ECG in isolation** - look for an underlying cause and treat that





**IT TAKES 10,000 HOURS TO BECOME AN  
EXPERT IN SOMETHING**

**BUT YOU DON'T NEED TO BE AN EXPERT.**

**YOU JUST NEED TO DO MORE ECGs**



# WE ARE HERE TO HELP



Echo Practical courses ~ 16 hours CPD ~ New Country House Hotel, Cardiff ~ Intro to Echo: 23 Sept & 21 Oct ~ Next steps in Echo: 14 Oct & 4 Nov ~ Su

## Welcome to HeartVets

HeartVets is an independent, specialist-led cardiology service for pets. We offer referral clinics in the South West UK and Wales, alongside telemedicine and education for veterinary professionals worldwide.

Join our community to receive our newsletter, cardiology tips and CPD details.



Holter Monitoring

ECG Services


Case Reviews

### Holter monitoring

Holter monitoring allows us to monitor heart rate and rhythm away from the clinic, to see how the heart responds during exercise or sleep and monitor arrhythmia burden. We work closely with carefully elected partners to bring the latest ECG technology and apparel to our service. Dogs and cats can both now be comfortably monitored in the stress-free environment of their own home.

Holter monitoring is an important tool in the following clinical scenarios:

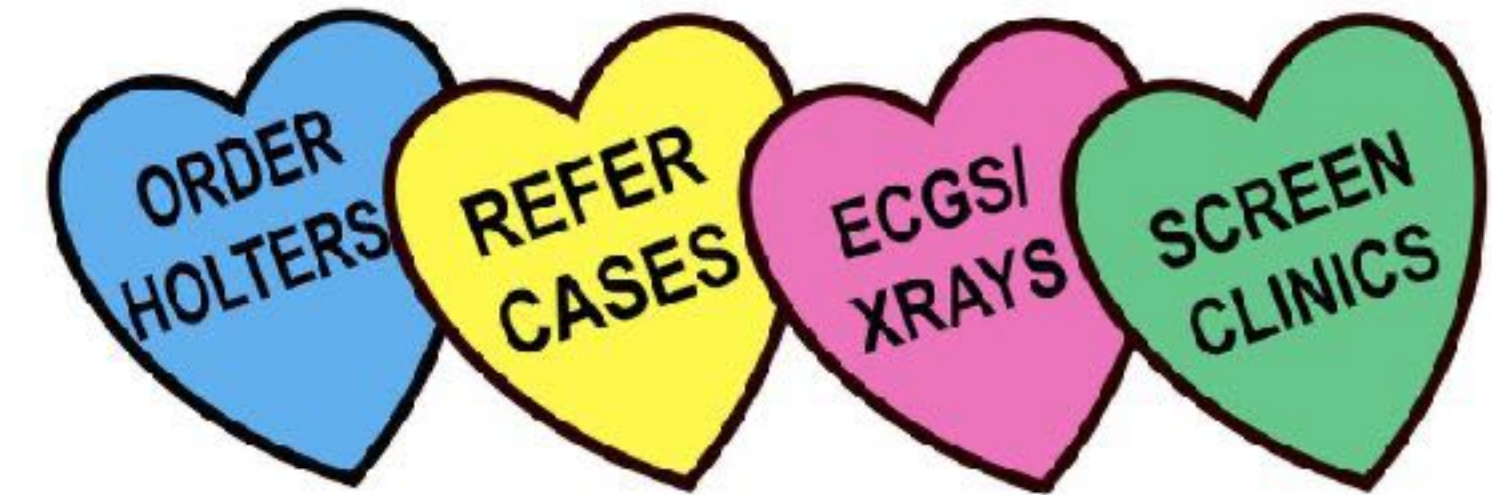- History of weakness, collapse or syncope (fainting)
- Assessing heart rate control in atrial fibrillation or congestive heart failure
- Identifying frequency, severity and associated risk of arrhythmias detected in the clinic
- Screening for arrhythmia in breeds at risk of cardiomyopathy e.g. Dobermans, Boxers, Great Danes, Irish Wolfhounds.
- Screening for arrhythmia or myocardial hypoxia ("heart attack" risk) in cats with hypertrophic cardiomyopathy (HCM).



# Thank you for listening

[dave@heartvets.co.uk](mailto:dave@heartvets.co.uk)

At  *HeartVets* we  
**LOVE**  
**HEARTS**®



[www.heartvets.co.uk](http://www.heartvets.co.uk)

